

The Fat Compartments of the Face: Anatomy and Clinical Implications for Cosmetic Surgery

Rod J. Rohrich, M.D.
Joel E. Pessa, M.D.

Dallas, Texas

Background: Observation suggests that the subcutaneous fat of the face is partitioned as distinct anatomical compartments.

Methods: Thirty hemifacial cadaver dissections were performed after methylene blue had been injected into specified regions. Initial work focused on the nasolabial fat. Dye was allowed to set for a minimum of 24 hours to achieve consistent diffusion. Dissection was performed in the cadaver laboratory using microscopic and loupe magnification.

Results: The subcutaneous fat of the face is partitioned into multiple, independent anatomical compartments. The nasolabial fold is a discrete unit with distinct anatomical boundaries. What has been referred to as malar fat is composed of three separate compartments: medial, middle, and lateral temporal-cheek fat. The forehead is similarly composed of three anatomical units including central, middle, and lateral temporal-cheek fat. Orbital fat is noted in three compartments determined by septal borders. Jowl fat is the most inferior of the subcutaneous fat compartments. Some of the structures referred to as “retaining ligaments” are formed simply by fusion points of abutting septal barriers of these compartments.

Conclusions: The subcutaneous fat of the face is partitioned into discrete anatomic compartments. Facial aging is, in part, characterized by how these compartments change with age. The concept of separate compartments of fat suggests that the face does not age as a confluent or composite mass. Shearing between adjacent compartments may be an additional factor in the etiology of soft-tissue malposition. Knowledge of this anatomy will lead to better understanding and greater precision in the preoperative analysis and surgical treatment of the aging face. (*Plast. Reconstr. Surg.* 119: 2219, 2007.)

Clinical observation and laboratory investigation suggest that the subcutaneous fat of the face exists in distinct anatomical compartments (Fig. 1). When the operating surgeon performs a face lift, zones of adherence are encountered that alternate with zones where dissection proceeds with relative ease. This suggests that barriers exist between different zones of facial fat.

Patients with facial atrophy and midface hollowing consistently show preservation of the nasolabial fold and jowl fat (Fig. 2). This common clinical observation suggests that regions of fat behave differently during the aging process.

In the cadaver laboratory, dye injected into the upper forehead flows down the cheek and into the neck in a distinct and reproducible manner. This test has been repeated at least a dozen times. Moreover, dye injected into the nasolabial fold partitions in a discrete fashion (Figs. 3).

Taken as a whole, these clinical and laboratory observations suggest that the subcutaneous fat of the face is highly partitioned, that it is not a confluent mass, and that further study is warranted to investigate this concept as it pertains to facial aging and cosmetic surgical techniques.

MATERIALS AND METHODS

Thirty hemifacial fresh cadaver dissections were performed on 18 male and 12 female specimens ranging in age from 47 to 92 years. Preliminary work was performed on multiple specimens to determine the best dye staining technique. Letraset, Bombay India Ink, indocyanine green, and methylene blue were all evalu-

From the Department of Plastic Surgery, University of Texas Southwestern Medical Center.

Received for publication July 27, 2006; accepted October 13, 2006.

Copyright ©2007 by the American Society of Plastic Surgeons

DOI: 10.1097/01.prs.0000265403.66886.54

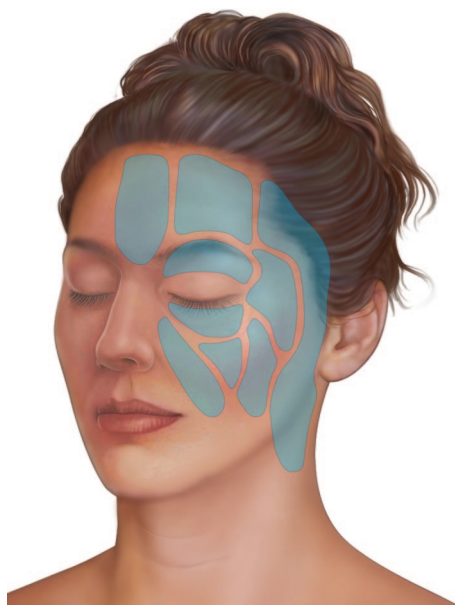

Fig. 1. An artist's rendition of the subcutaneous compartments of the face.

ated. Methylene blue consistently displayed the best tissue diffusion.¹ In other studies, rehydrating some of the specimens was found to improve dye diffusion.

Dye was allowed to set for a minimum of 24 hours to allow for adequate tissue diffusion. Allowing the dye to set for 48 to 72 hours actually improved distribution and facilitated dissection. Each compartment was verified by injecting a minimum of three and a maximum of 10 cadaver hemifaces. All work was performed in the cadaver laboratory.

Microscopic and 4.5- and 6.0-power loupe magnification facilitated dissection. Photographic documentation was obtained with a Canon 20D system and F2.8 macro lens. Images were scanned into Adobe Photoshop (CS2; Adobe Systems, Inc., San Jose, Calif.). All results are shown from the cadaver's left side for the sake of consistency.

RESULTS

Nasolabial Fat Compartment

The nasolabial fat was injected in 10 hemifaces from three male and two female cadavers. The cadaver face was allowed to set at least 24 hours, although immediate staining of a distinct area could be seen through the skin. A distinct compartment was noted in all specimens (Fig. 4). The nasolabial fat lies anterior to medial cheek fat, and overlaps jowl fat. The orbicularis retaining ligament represents the superior border of this com-

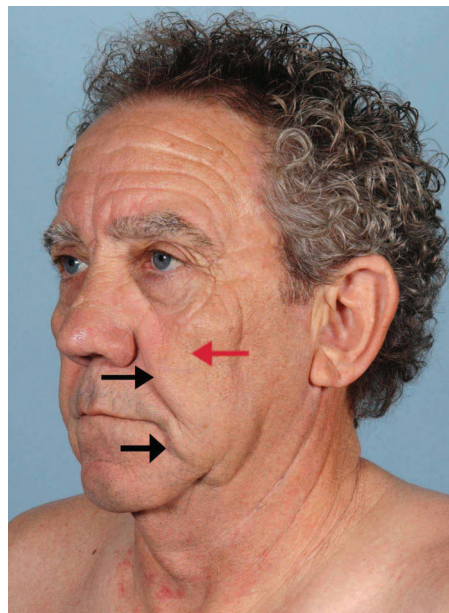


Fig. 2. Lipatrophy and midface hollowing (*red arrow*) are noted with preservation of the nasolabial and jowl fat (*black arrows*).

partment. Nasolabial fat can be noted medial to the deeper fat of the suborbicularis fat compartment. The lower border of the zygomaticus major muscle is adherent to this compartment.

As an incidental observation, the volume of this compartment did not vary much between cadavers, regardless of age or sex. The only variable noted was that medial cheek fat overlapped nasolabial fat to a greater degree in certain cadavers.

Cheek Fat Compartments

There are three distinct cheek fat compartments: the medial, middle, and lateral temporal-cheek fat.

Medial cheek fat is lateral to the nasolabial fold (Fig. 5). This compartment is bordered superiorly by the orbicularis retaining ligament and the lateral orbital compartment. Jowl fat lies inferior to this fat compartment.

Middle cheek fat lies superficial in its midportion (Fig. 6). This fat compartment is found anterior and superficial to the parotid gland. At its superior portion, the zygomaticus major muscle is adherent. A confluence of septa occurs at this location where three compartments meet, and forms a dense adherent zone where the zygomatic ligament has been described.²

The fusion of septal boundaries is an anatomical principle and can be simply illustrated by cross-sectional anatomy (Fig. 6, *right*). Middle cheek fat abuts medial cheek fat, and their septal

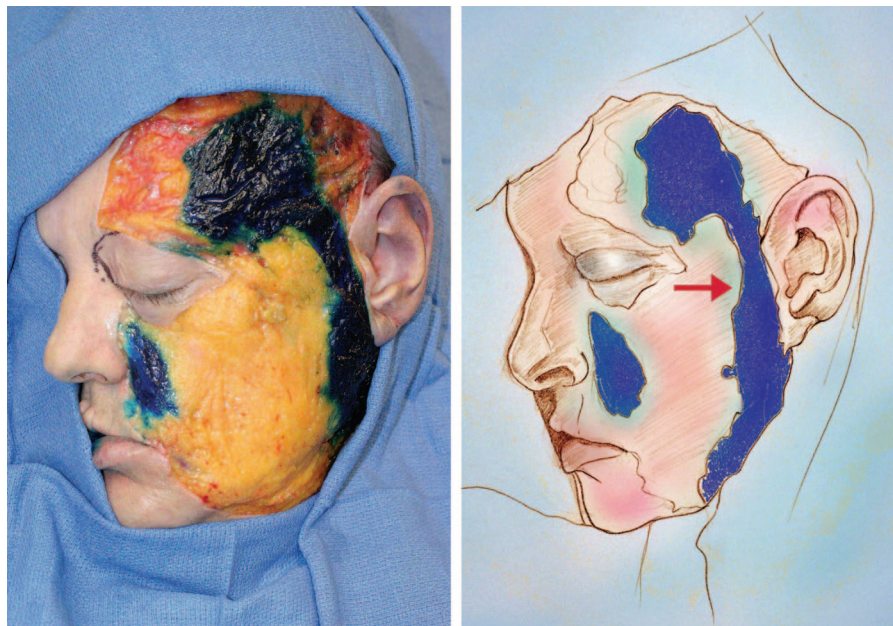

Fig. 3. (Left) Methylene blue dye injected into the forehead flows down the cheek in a specific and reproducible manner. The nasolabial fat also stains as a specific region. (Right) An artist's rendition of how dye flows from the forehead to the neck with a distinct medial boundary (arrow). Dye partitioning would not occur if the face were a confluent mass.

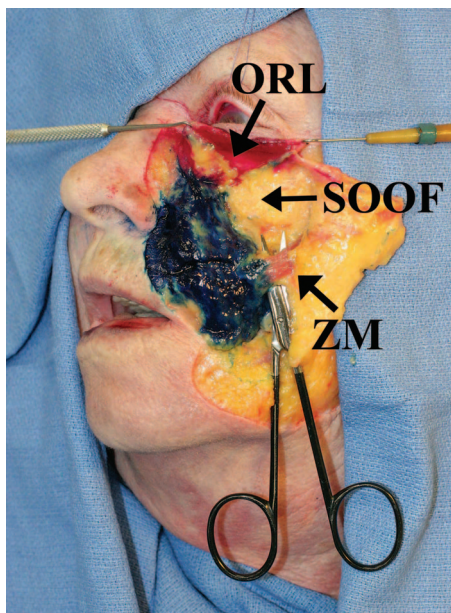


Fig. 4. The nasolabial fat compartment is the most medial of the major cheek compartments. Blue dye has stained this region. The orbicularis retaining ligament is the superior boundary (ORL), and the suborbicularis fat is a lateral and deep boundary (SOOF). Medial cheek fat has been reflected off the nasolabial compartment. The zygomaticus major is tethered at its inferior border (ZM).

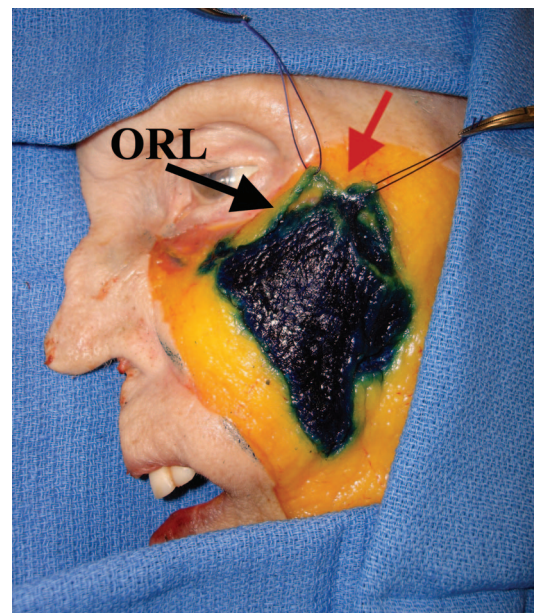


Fig. 5. Malar fat is composed of three compartments: the medial, middle, and lateral temporal-cheek. The medial fat, shown here, lies adjacent to the nasolabial fat. The superior boundary is again the orbicularis retaining ligament (ORL). The lateral boundary is the middle cheek septum. The red arrow represents a point of fixation.

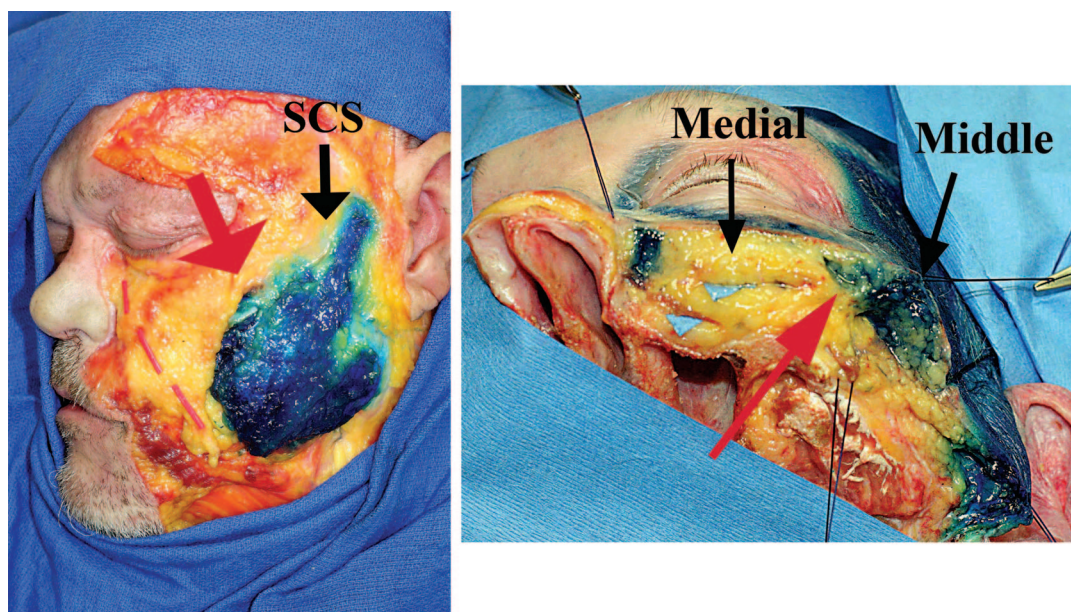


Fig. 6. (Left) The middle cheek fat compartment lies between medial and lateral temporal-cheek fat. The superior border is defined by the superior cheek septum (SCS). A zone of fixation (red arrow) is noted where this compartment adjoins the middle compartment and inferior orbital compartment. (Right) The cross-sectional anatomy illustrates the anatomic principle that fusion planes exist between adjacent fat compartments. A dense fascial system (red arrow) exists where the medial and middle fat compartments meet. The zygomaticus major muscle is noted deep to this fusion plane.

boundaries fuse into a dense fascial network (Fig. 6, right, arrow). Again, this corresponds to what has been described as the zygomatic ligament. The zone where the medial fat abuts the middle cheek fat corresponds to the location of the parotidomasseteric ligaments.³

The lateral temporal-cheek compartment is the most lateral compartment of cheek fat (Fig. 7). This fat lies immediately superficial to the parotid gland and connects the temporal fat to the cervical subcutaneous fat.

A true septum can be located anterior to this compartment. This septum, the lateral cheek septum, can be dissected and clearly identified as a vertical septal barrier with loupe magnification. This is the first transition zone encountered during a face lift when proceeding medially from the preauricular incision.

Forehead and Temporal Fat Compartments

The subcutaneous fat of the forehead is composed of three compartments. The central compartment is located in the midline region of the forehead (Fig. 8). It has a consistent location that abuts the middle temporal compartments on either side and has an inferior border at the nasal dorsum. The lateral boundary probably is a septal

barrier and could be referred to as the central temporal septum.

The middle temporal fat compartments lie on either side of the central forehead fat (Fig. 9). The inferior border is the orbicularis retaining ligament, and the lateral border corresponds to the superior temporal septum.⁴

The lateral temporal-cheek compartment has previously been described. It connects the lateral forehead fat to the lateral cheek and cervical fat (Fig. 7).

Orbital Fat Compartment

Three subcutaneous fat compartments exist around the eye. The most superior compartment is bounded by the orbicularis retaining ligament as it courses around the superior orbit (Fig. 10). The orbicularis retaining ligament is a truly circumferential structure that spans the superior and inferior orbits and blends into the medial and lateral canthi. Dye injected into the superior compartment does not stain the inferior orbital compartment.

The inferior orbital fat is a thin, subcutaneous layer that lies immediately below the inferior lid tarsus (Fig. 11). Its inferior boundary is the orbicularis retaining ligament or malar septum. The medial and lateral extents are, again, the canthi.

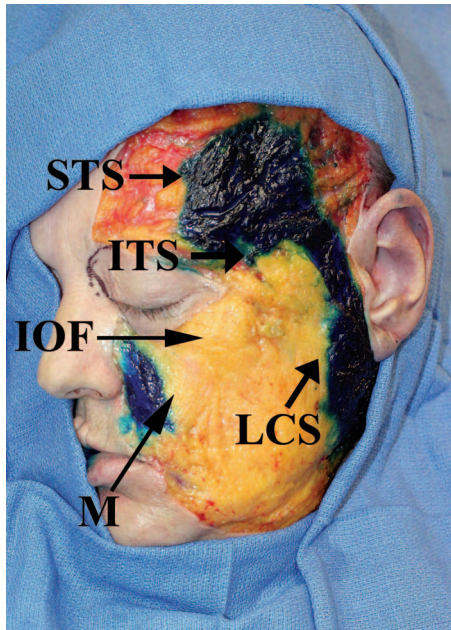


Fig. 7. The lateral temporal-cheek fat spans the forehead to the cervical region. It is the most lateral of the cheek fat compartments and has an identifiable septal barrier medially called the lateral cheek septum (*LCS*). The superior and inferior temporal septa (*STS* and *ITS*, respectively) represent the superior boundaries. This cadaver dissection is noteworthy because several fat compartments are seen without dye staining, including the inferior orbital fat (*IOF*) and medial cheek fat (*M*). Nasolabial fat has been stained with methylene blue dye.

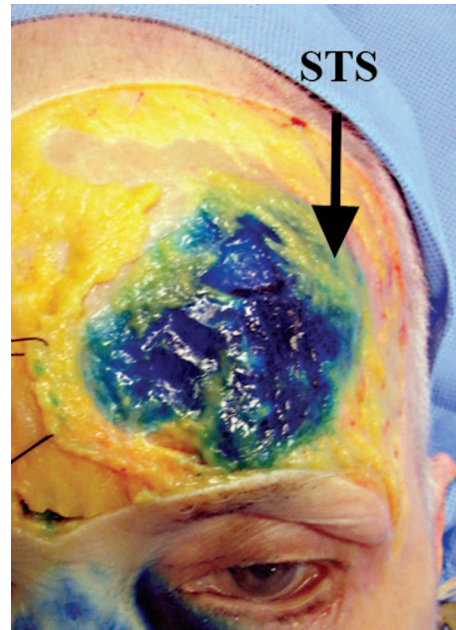


Fig. 9. The middle forehead fat compartments are situated on either side of the central fat and are located medially to the superior temporal septum (*STS*). The inferior border is the orbicularis retaining ligament of the superior orbit. The lateral temporal-cheek fat has already been described and is the third of the forehead fat compartments.

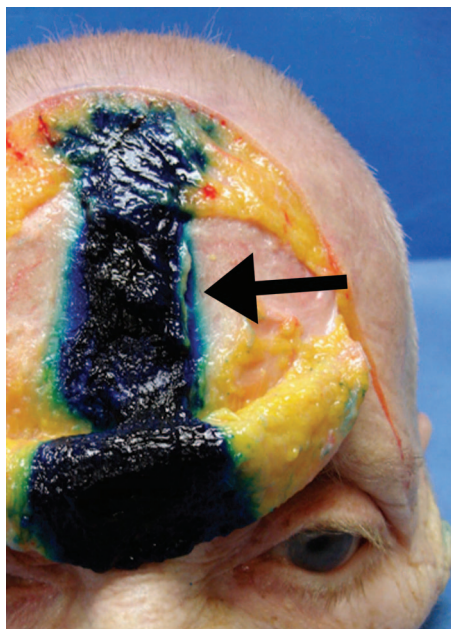


Fig. 8. Three forehead fat compartments have been identified to date. The central fat is a midline region. It has an inferior boundary at the nasal dorsum. The lateral border is a dense fascial plane that appears to be a septum, termed the central temporal septum.

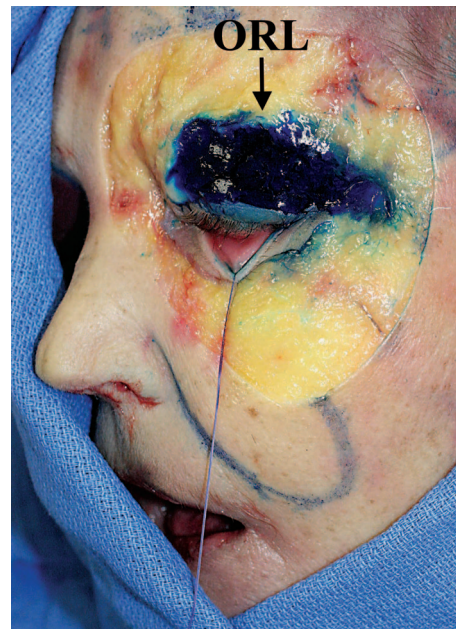

Fig. 10. There are three periorbital fat compartments. The superior orbital fat is shown here. The boundary is the orbicularis retaining ligament (*ORL*), a truly circumferential membrane that inserts at the medial and lateral canthi. The superior and inferior orbital compartments are, however, distinct from one another.

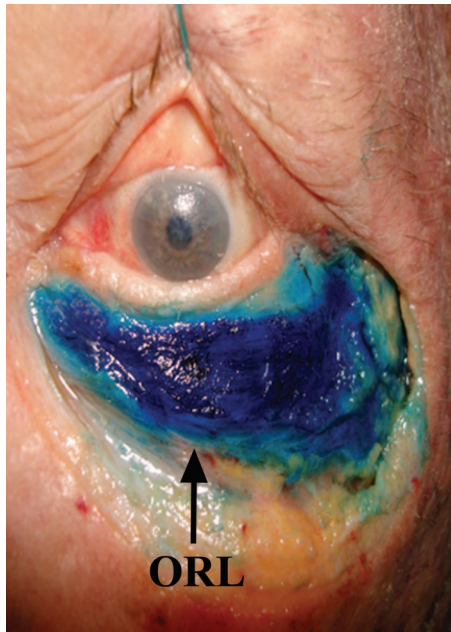

Fig. 11. The inferior orbital fat compartment is analogous to the superior orbital fat and, again, is bordered by the orbicularis retaining ligament (*ORL*). This compartment is noted clinically with periorbital ecchymosis.

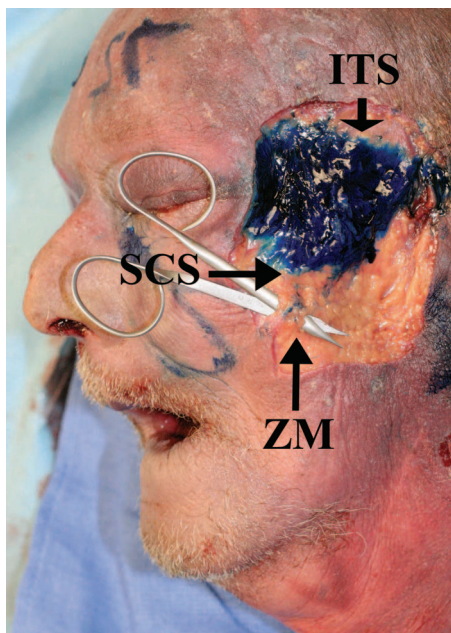


Fig. 12. The lateral orbital fat lies below the inferior temporal septum (*ITS*) and above the superior cheek septum (*SCS*). The zygomaticus major muscle is adherent superiorly (*ZM*). Interestingly, the zygomaticus muscle is adherent to several fat compartments. This is clinically important, because dissection past the zygomaticus major is necessary to move or alter medial cheek fat.

The lateral orbital fat compartment is the third of the subcutaneous orbital fat compartments (Fig. 12). Its superior border is the inferior temporal septum⁴; the inferior border is designated the superior cheek septum. The zygomaticus major muscle is again noted to be adherent to this compartment. Transitioning the zygomaticus major muscle plays a major role in adequately releasing soft tissues if one attempts to elevate medial fat or jowl fat.

Jowl Fat Compartment

Jowl fat is separate from nasolabial fat (Fig. 13, *left*). Jowl fat adheres to the depressor anguli oris muscle. The medial boundary of this compartment is the lip depressor muscle, and the inferior boundary is determined by a membranous fusion of the platysma muscle. The fusion point between these two muscles occurs at the region of the mandibular retaining ligament.² The difference between nasolabial fat and jowl fat can be shown by cross-sectional anatomy (Fig. 13, *right*).

DISCUSSION

This study suggests that facial subcutaneous fat is highly compartmentalized. Because the face is composed of multiple discrete anatomical regions, it is unlikely that it ages as a confluent mass.

A youthful face is characterized by a smooth transition between subcutaneous compartments: aging leads to abrupt contour changes between these regions. This may occur due to volume loss as described by Lambros⁵ or to malposition of specific compartments from a number of causes. Attenuation of ligaments alone would be insufficient to explain compartment changes, especially in light of the septated architecture of the fat compartments noted herein.

This anatomical arrangement is in agreement with that noted clinically. The operating surgeon encounters areas of fixation or adherence in dissecting from lateral to medial. These areas are vascular and occur in the transition region between compartments. The zygomatic major muscle provides an important area of fixation to three compartments, and dissection becomes much easier once the zygomaticus muscle is transitioned. The plane between the lateral and middle cheek compartments can easily lead into the buccal fat; again, the zygomatic major muscle is a major landmark in avoiding this pitfall. As a clinical point, if one chooses to dissect medially to elevate jowl fat, dissection has

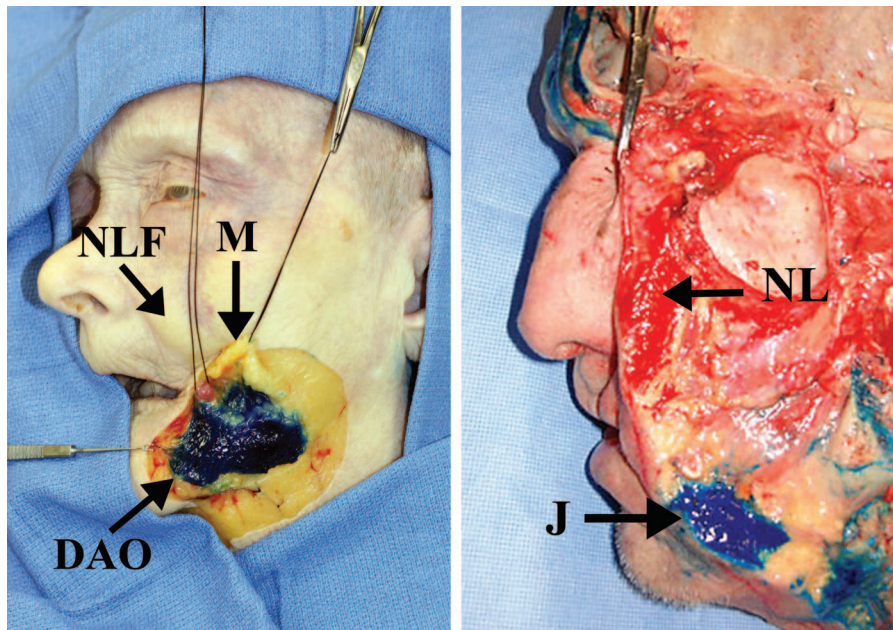


Fig. 13 (Left) Jowl fat is the most inferior fat on the face. It is bounded medially by the depressor anguli oris muscle (DAO). The relationship of this muscle to the compartment may be analogous to that of the zygomaticus major and its adjacent fat compartments. Nasolabial fat (NLF) and medial fat (M) are located superiorly. This is the least understood of the fat compartments described and may be the most important in terms of midfacial aging. How this compartment behaves during the aging process is not known. (Right) Vertical cross-sectional anatomy illustrates that jowl fat is separate from nasolabial fat. The nasolabial fold (NL) has been injected with red latex, and the jowl has been injected with blue latex (J). Intervening upper lip fat is noted, as well as the labial artery.

to proceed medially to the zygomaticus major muscle to free the fat compartments from their adherence to this muscle.

Ligaments may be formed where septal barriers and fat compartments meet. This is apparent in the zygomatic area, where the inferior orbital, lateral orbital, and middle cheek compartments meet. This is a highly vascular area that corresponds to the zygomatic ligament. This fusion area represents an area of risk to the facial nerve, due to the tethering function where several compartments merge.

The area beneath the ear is another point of fusion. The lateral temporal-cheek compartment ends right in front of the ear. There is a postauricular fat compartment that abuts this. Between these two compartments, a septal fusion occurs that represents a barrier. What is thought of as the platysma ligament² may simply be a fusion point between two compartments. If the operating surgeon is not aware of this fusion region, it places the greater auricular nerve at risk by improper transition of the subcutaneous plane at this point.

Other examples exist of fusion planes between compartments. The mandibular ligament occurs where the submental crease (platysma skin insertion) fuses with the origin of the depressor anguli muscle, and then across the lower border of the mandible. The parotido-masseteric ligaments correspond to the plane between the middle and medial cheek fat compartments (medial cheek septum). Fusion planes occur in many regions of the face, in both the transverse and vertical directions.

This anatomy is not entirely without precedent. Whetzel and Mathes described the arterial anatomy of the face using several dye techniques⁶ and expanded Taylor and Palmer's concept of angiosomes to the face, forehead, and neck.⁷ It is of interest that in their article, the authors show perforating vessels in cross-sectional anatomy that occur exactly in the same location as the transition zone between fat compartments seen in Figure 6, right. This is in accord with the clinical observation that transition zones between subcutaneous fat compartments are highly vascular. These fat compartments are

not angiosomes; rather, they occur between vascular perforating vessels that supply the skin. More evidence is the important role played by the zygomaticus major and depressor anguli oris muscles, which may have myocutaneous perforators traveling in septa.

Deep layers of facial fat, including the sub-orbicularis, retro-orbicularis, and buccal fat, have been studied in detail.⁸⁻¹¹ This study suggests that additional deep fat compartments exist (Fig. 6, *right*). For example, a fat compartment surrounds the levator anguli muscle, and there exists a fat compartment beneath the lip elevator muscles. A tenet of facial anatomy is that fat is noted both above and below most facial muscles, probably to facilitate the necessary gliding mechanism.

With this knowledge in mind, the aging face can be analyzed as a change in volume and position of these separate compartments, both superficial and deep (Fig. 2). The cadaver shown in Figure 2 has a loss of midfacial projection, prominence of the nasojugal crease, malar mound show, jowl prominence, and a deep nasolabial fold. These findings are not unrelated.

Jowl prominence may occur from malposition of the labiomandibular compartment. In addition, loss of volume of the deep midfacial fat (Fig. 14) may be a primary determinant of midfacial aging. This decreases support for the medial cheek compartment and results in diminished midface projection. The nasolabial fold is unmasked, just as is the malar mound. A cascade occurs from malposition of this compartment. The negative vector, caused by loss of support for the medial cheek compartment and volume loss of the deep compartment fat, allows excess traction to be placed on the lower eyelid.¹² This leads to scleral show. Confirmatory evidence for this last statement is noted clinically by the snap test¹³: if a prolonged amount of time is noted for an individual's lower lid to return to the normal position, this can be improved by simple medial cheek elevation. Lid laxity, orbicularis laxity, and loss or attenuation of the canthi may play a small or no role in what is actually encountered clinically. Rather, subcutaneous fat malposition and atrophy simply place downward traction on the lower lid and distorts its position.

We suggest that jowl fat may be an important key to rejuvenating the midface. In the cadaver laboratory, dissection of the nasolabial fat and repositioning of this compartment beneath the medial cheek fat can efface the nasolabial fold (Fig. 14). Perhaps

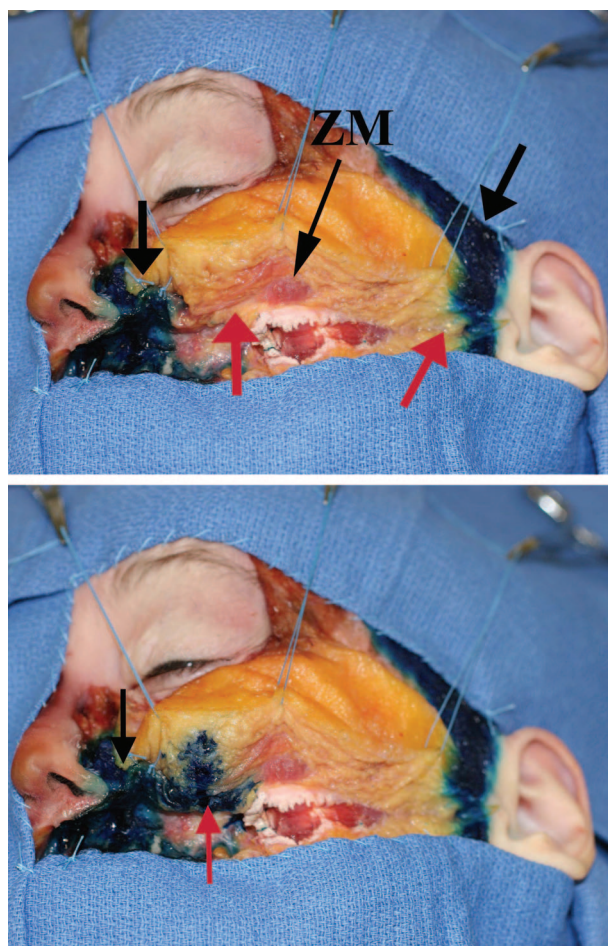


Fig. 14. The nasolabial fat compartment can be repositioned beneath the medial cheek fat compartment experimentally to diminish the contour deformity. Understanding the anatomic compartments explains why simple lateral traction of skin or skin and fat has little overall effect on the nasolabial fold prominence. This technique may be applicable to jowl fat and midface projection. (*Above*) The nasomaxillary fat is seen medially (*black arrow*). The deep compartment fat—the deep midfacial fat—is noted by the *red arrow*. This has not been previously described. There is likewise a lateral deep compartment fat (*red arrow laterally*) beneath the lateral temporal-cheek compartment (ZM, zygomaticus major muscle). (*Below*) The deep midfacial fat has been injected with methylene blue dye (*red arrow*), which stains around the levator anguli oris muscle. This deep compartment may be a primary determinant of a youthful, anteriorly projecting midface. Loss of volume in this deep compartment, similar to what may occur in the temporal fat, may lead to the cascade effect described.

this technique will find application in repositioning attempts of the jowl fat.

The eye sees what the mind knows. The concept of subcutaneous fat compartments shifts one's perspective from visualizing the face as a

discrete mass to viewing the face as a set of architectural compartments. These compartments may age independently, and mass shifts of facial soft tissue may not sufficiently address the complexity of the aging process. The answers to this and many other questions suggested by this study await further research.

Joel E. Pessa, M.D.

Department of Plastic Surgery
5323 Harry Hines Boulevard
Dallas, Texas 75390-9132
joel.pessa@utsouthwestern.edu

ACKNOWLEDGMENTS

The authors thank Melinda Mora of the University of Texas Southwestern Willed Body Program. This study would not have been possible without her help. Kind thanks are also extended to Holly Smith, from the medical illustration department, for her help in preparing the article.

DISCLOSURE

The authors have no financial interests in this research project or in any of the techniques or equipment used in this study.

REFERENCES

1. Ahlberg, K. M., Assavanop, P., and Tay, W. M. A comparison of the apical dye penetration patterns shown by methylene blue and India ink in root-filled teeth. *Int. Endod. J.* 28: 30, 1995.
2. Furnas, D. W. The retaining ligaments of the cheek. *Plast. Reconstr. Surg.* 83: 11, 1989.
3. Stuzin, J. M., Baker, T. J., and Gordon, H. L. The relationship of the superficial and deep facial fascias: Relevance to rhytidectomy and aging. *Plast. Reconstr. Surg.* 89: 441, 1992.
4. Moss, C. H., Mendelson, B. C., and Taylor, G. I. Surgical anatomy of the ligamentous attachments in the temple and periorbital regions. *Plast. Reconstr. Surg.* 105: 1475, 2000.
5. Lambros, V. Personal communication. July 2006.
6. Whetzel, T. P., and Mathes, S. J. Arterial anatomy of the face: An analysis of vascular territories and perforating cutaneous vessels. *Plast. Reconstr. Surg.* 89: 591, 1992.
7. Taylor, G. I., and Palmer, J. H. The vascular territories (angiosomes) of the body: Experimental study and clinical applications. *Br. J. Plast. Surg.* 40: 113, 1987.
8. Aiache, A. E., and Ramirez, O. H. The suborbicularis oculi fat pads: An anatomic and clinical study. *Plast. Reconstr. Surg.* 95: 37, 1995.
9. May, J. W., Jr., Fearon, J., and Zingarelli, P. Retro-orbicularis oculi fat (ROOF) resection in aesthetic blepharoplasty: A 6-year study in 63 patients. *Plast. Reconstr. Surg.* 86: 682, 1990.
10. Stuzin, J. M., Wagstrom, L., Kawamoto, H. K., Baker, T. J., and Wolfe, S. A. The anatomy and clinical applications of the buccal fat pad. *Plast. Reconstr. Surg.* 85: 29, 1990.
11. Jackson, I. T. Anatomy of the buccal fat pad and its clinical significance. *Plast. Reconstr. Surg.* 103: 2059, 1999.
12. Jelks, G. W., and Jelks, E. B. Preoperative evaluation of the blepharoplasty patient: Bypassing the pitfalls. *Clin. Plast. Surg.* 20: 213, 1993.
13. Furnas, D. W. Festoons, mounds, and bags of the eyelids and cheek. *Clin. Plast. Surg.* 20: 367, 1993.