



The Canadian Pediatric Thyroid Nodule Study: an evaluation of current management practices

The Canadian Pediatric Thyroid Nodule (CaPTN) Study Group¹

Received 16 November 2007; accepted 3 December 2007

Key words:

Thyroid nodule;
Child;
Adolescent;
Thyroidectomy;
Fine needle aspiration
cytology;
Thyroid malignancy

Abstract

Background/Purpose: Thyroid nodules in children often require surgical treatment. We evaluated management practices for these across Canada.

Methods: Patient records from 9 Canadian pediatric centers of children undergoing surgery for thyroid nodules over a 6-year period were reviewed. Demographics, presenting features, investigations, surgical treatment, pathology, and complications were assessed.

Results: One hundred and forty-one patients were reviewed (75% female), of whom 117 presented with a palpable mass. Ultrasound and/or thyroid scintigraphy was the most commonly used preoperative imaging studies. Fine-needle aspiration cytology correlated with final pathology in 49% of cases. Overall, the rate of malignancy in this series was 43%, with half being papillary carcinoma. Thirty-two of 57 patients undergoing primary total thyroidectomy had a malignancy; 14 of these had positive preoperative fine-needle aspiration cytologies. Twenty of 71 patients undergoing initial hemithyroidectomy ± isthmusectomy had a malignancy. Seventeen of these went on to completion thyroidectomy and 3 had malignancy in the second specimen. Hypocalcemia and hoarseness occurred in 14 and 4 patients, respectively. Complications were more common after primary total thyroidectomy; none occurred in patients undergoing completion thyroidectomy.

Conclusions: The incidence of malignancy in pediatric thyroid nodules is high, and the risk of surgical complications significant. With variable management practices across Canada, evidence-based guidelines for diagnosis and surgical treatment may be valuable.

© 2008 Elsevier Inc. All rights reserved.

The incidence of thyroid nodules in children is relatively uncommon compared to adults [1]. Furthermore, the management of these lesions tends to be more aggressive,

owing to a perceived increased risk of malignancy in the pediatric population, particularly for younger patients with thyroid nodules. The Canadian Pediatric Thyroid Nodule

Presented at the 39th Annual Meeting of the Canadian Association of Pediatric Surgeons, August 23–26, 2007, St John's, Newfoundland, Canada.

* Corresponding author. The Division of Pediatric Surgery, The Montreal Children's Hospital, Montreal, QC, Canada H3H1P3. Tel.: +1 514 412 4438; fax: +1 514 412 4341.

E-mail address: pramod.puligandla@muhc.mcgill.ca (P. Puligandla).

¹ Chris Stevens, Husain Al-Mahmeed and Geoff Blair (Coinvestigator) - British Columbia Children's Hospital, Vancouver, BC, Canada; Pascale Prasil - Centre Hospitalier de l'université Laval, Laval, Quebec, Canada; Fayza Haider and Brian Sweeney - Children's Hospital of Eastern Ontario, Ottawa, Ontario, Canada; Kyle Cowan and Andreana Butter - Children's Hospital of Western Ontario, London, Ontario, Canada; Anthony deBuys Roessingh and Sarah Bouchard - Hôpital Ste-Justine, Montreal, Quebec, Canada; Robert Weinsheimer and Natalie Yanchar (Coinvestigator) - IWK Health Centre, Halifax, Nova Scotia, Canada; Sarah Jones - Kingston General Hospital, Kingston, Ontario, Canada; Wasmi Alfadhli and Peter Fitzgerald - McMaster Children's Hospital, Hamilton, Ontario, Canada; Jon Ryckman and Pramod Puligandla* (Principal investigator) - The Montreal Children's Hospital, Montreal, Quebec, Canada.

0022-3468/\$ – see front matter © 2008 Elsevier Inc. All rights reserved.

doi:10.1016/j.jpedsurg.2007.12.019

(CaPTN) Study Group, consisting of 9 pediatric tertiary care centers, was created to better assess the features and management of thyroid nodules in children across Canada. The objective of the current study was (1) to estimate the incidence of variables associated with malignancy of thyroid nodules in children in Canada, and (2) to evaluate the current management practices for pediatric thyroid nodules across the country, including preoperative investigations, surgical procedures, complications, and outcomes.

1. Methods

With institution-specific ethics review board approval, retrospective chart reviews were performed at each collaborating center for all cases of children with a diagnosis of thyroid nodule(s) between January 1, 2000, and December 31, 2005. Potential medical records for review were identified using the International Classification of Diseases (ICD10) codes reflecting thyroid pathology (19.05-19.19, 19.21, 19.22, 19.29, 19.39, 19.41, 19.42, 19.43, 19.5, 19.81, 19.82, 19.91-19.95) and all cases identified as having undergone a surgical procedure on the thyroid gland (thyroidectomy, any type). Charts were included for study if the review revealed a case presenting with a thyroid nodule.

Data variables collected included: patient demographics, factors associated with the development of thyroid carcinoma, clinical presentation, imaging and laboratory investigations, surgical procedures performed, and pathology. Individual study site data, cleared of personal identifiers, were sent to the main study site (The Montreal Children's Hospital) using anonymous identification codes and entered into a master spreadsheet. Descriptive analyses were performed using standard methods. All means were expressed with standard deviations. Student *t* test was used to compare continuous variables, whereas the χ^2 analysis was used for categorical variables. Logistic regression analysis was used to identify associations between clinical and historical features that could predict the presence of a malignant thyroid lesion. A *P* value less than .05 was considered statistically significant. All analyses were performed using the Statistical Program for Social Sciences version 14.0 (SPSS Inc, Chicago, Ill) after consultation with the Clinical Research Centre located at the main study site.

2. Results

A total of 141 patients (106 female/35 male) were entered into the database. The overall mean age of patients at operation was 155 ± 46 months with a range of 31 to 217 months. The mean age of patients with proven benign disease ($n = 81$; 155 ± 48 months; range, 31-217 months) was not statistically different from those with malignancy

Table 1 Factors associated with the development of thyroid malignancy

Factor	n	<i>P</i> value	95% CI
Family history of thyroid carcinoma (any)	23/132	.91	0.41-2.71
Family history of MEN or MTC	15	N/A	—
Family history of other malignancy	20/131	N/A	—
Family history of thyroid disorder	40/131	N/A	—

P value refers to the significance of the factor as a predictor of a malignant nodule based on logistic regression analysis. *P* values < .05 were considered statistically significant. CI indicates confidence interval; N/A, not assessed.

($n = 60$; 155 ± 44 months; range, 45–215 months; $P = .871$). Those patients with a family history of multiple endocrine neoplasia (MEN) or medullary thyroid carcinoma (MTC) were significantly younger at the time of operation than those with benign disease ($n = 15$; 107.0 ± 30.9 ; range, 45–203 months; $P = .003$). Associations between variables reflecting clinical and family history and the risk of malignancy in the nodule are shown in Table 1. No statistically significant relation between a positive family history for thyroid malignancy (other than familial MTC) and the future development of thyroid cancer could be found. Seven patients in this series had received treatment for an antecedent malignancy. Five of these patients had received radiotherapy as part of their treatment protocol, of whom 4 developed papillary carcinoma.

The most common presenting feature was the presence of a mass within the thyroid gland (117/137). Other indications for clinical evaluation included the presence of cervical lymphadenopathy (3), symptoms of hyper- or hypothyroidism (9), the need for a screening examination (family history of MEN—5, previous radiotherapy—1, a “firm gland”—1), and the identification of an incidental thyroid lesion on imaging performed for an unrelated reason. The data for presenting features were incomplete for the remaining 4 patients. Other presenting features are listed in Table 2. Preoperative laboratory investigations most commonly included serum thyroxine (T_4) and thyroid-stimulating hormone (TSH) levels. Radiologic investigations included ultrasonography in 87% of cases (119/137), thyroid scintigraphy in 50%, computed tomography in 17%, and magnetic resonance imaging in only 1 case. Seven patients had no radiological imaging before the operative procedure: 2 with MEN syndrome, 3 with complications of Graves' disease, 1 with hypothyroidism and a firm gland, and 1 who only presented with a mass; all of these patients underwent total thyroidectomy. Fine-needle aspiration cytology (FNAC) was performed in 59% of patients (81/137), but only half of these aspirates contained sufficient cellular material to make a cytologic interpretation. All patients who underwent FNAC

Feature	n	P value	95% CI
Lymphadenopathy	16/136	.142	0.09-1.42
Growth of mass over time	29/136	.060	0.20-1.04
Voice changes	6/135	.575	0.08-4.08
Pain	6/134	.140	0.02-1.75
Hyperthyroidism	16/134	N/A	–
Other symptoms (fatigue, anxiety, etc)	31/130	N/A	–

P-value refers to the significance of the feature as a predictor of a malignant nodule based on logistic regression analysis. *P* values < .05 were considered statistically significant.

had some form of thyroid resection. Two complications of FNAC were reported (1 hematoma, 1 with pain).

The types and distribution of thyroidectomy procedures performed for thyroid nodules are shown in Fig. 1. The most common initial procedure performed was hemithyroidectomy ± isthmusectomy (n = 71); 20 (28%) of these patients had malignancy in the resected specimen. Of these, 17 proceeded to completion thyroidectomy, with 3 having malignancy in the second specimen. Fifty-seven patients underwent a primary total thyroidectomy, of whom 14 had determinate cytology on the preoperative FNAC to help guide the choice of operative procedure. The other indications for primary total thyroidectomy included a family history of MEN/MTC (15) and complications related

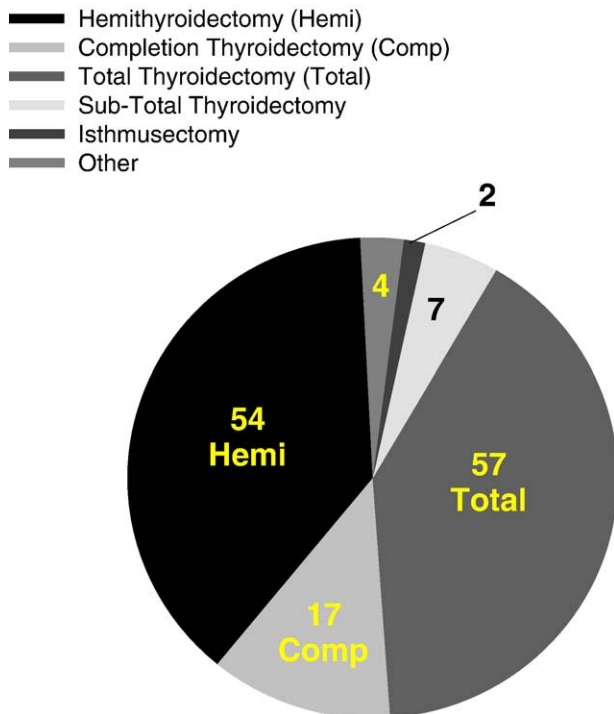


Fig. 1 Pie graph demonstrating the type and number of thyroidectomy performed. Patients undergoing completion thyroidectomy previously had a hemithyroidectomy. “Other” refers to nodulectomy or partial thyroid lobectomy.

Pathology	Total (N = 57)	Subtotal (n = 7)	Hemi (n = 71)	Isthmus (n = 2)	Other (n = 4)
Malignant					
Papillary	22	5	16	1	
Follicular variant			2		
Follicular			1		
Medullary	10				
Other		1	1		1
Benign					
Adenoma	2	1	37	1	1
Goiter	7		4		
Hyperplasia	4		5		
Graves	8				
Hashimoto			3		
Normal	4		1		1
Other			1		1

“Other” refers to nodulectomy or partial thyroid lobectomy. The 4 patients who had normal pathology after total thyroidectomy underwent the procedure as a prophylactic measure for MEN syndrome or familial MTC.

to the medical management of Graves’ disease (8). The remaining patients underwent total thyroidectomy at the discretion of the surgeon. Malignant lesions were found in 56% (22 papillary and 10 MTC) of patients undergoing total thyroidectomy, whereas benign lesions were identified in 30%. Regional lymphadenectomy was performed at the initial procedure in 32 of 111 patients. The overall incidence of malignancy in this series, based on the surgical pathology, was 43%. Fifteen patients had family histories significant for MEN syndromes or MTC, of whom 7 had confirmed genetic testing before thyroidectomy. Ten of these patients had MTC in the surgical specimen. The surgical pathology based on the initial surgical procedure performed is shown in Table 3.

Postoperative complications included hypocalcemia (14) and hoarseness (4), and were most frequent after primary total thyroidectomy (11 and 3, respectively). The incidence of postoperative hypocalcemia was significantly higher in those undergoing primary total thyroidectomy compared to hemithyroidectomy (11/57 vs 3/71; *P* < .01). Three permanent recurrent laryngeal nerve injuries were also reported, 2 after total thyroidectomy and 1 after subtotal thyroidectomy. No patient experienced these complications after the staged procedure (completion thyroidectomy after a hemithyroidectomy).

3. Discussion

Although thyroid nodules in children are uncommon [1,2], the risk of malignancy within these lesions has been estimated to be 4-fold higher than for adults [2]. Based on this information, it may not be reasonable that the treatment

regimens for children and youth with thyroid malignancies be aligned with adult protocols.

Our results demonstrate a 43% incidence of malignancy in pediatric thyroid nodules treated by surgical resection. Although this level is higher than recently published estimates [1,3,4], it does not take into account those patients who may have undergone observation alone and is likely an overestimate. The use of hospital discharge data to identify cases for this database precluded determination of such patients, who would generally be followed on an outpatient basis. Contrary to some reports suggesting a higher incidence of malignancy in younger children with thyroid nodules [3], the age for children with and without malignancy in this series was not significantly different. However, those children undergoing thyroidectomy for family histories significant for MEN syndromes or MTC were much younger than the study population as a whole. This is in keeping with current recommendations that suggest early prophylactic total thyroidectomy for patients with inheritable mutations causing thyroid malignancy [5]. This is particularly true for those children with an identified RET gene mutation, who may require thyroidectomy as early as 1 year of age.

The high incidence of malignancy in this series suggests that each child with a thyroid nodule must be carefully evaluated. Although clinical examination often demonstrated the presence of a mass, the clinical characteristics of growth over time, pain, and lymphadenopathy could not be

correlated with the presence of a malignant lesion in this series. These results are generally concordant with other published series [1,2,6], although lymphadenopathy and growth of the nodule over time have been suggested to be predictive of malignant disease by other authors [2,3]. Furthermore, no correlation between factors historically associated with the development of thyroid malignancy, such as a family history of thyroid cancer (excluding those with MEN or MTC), could be determined. A possible explanation for this could be the wide distribution of familial thyroid problems throughout the study population as opposed to a specific subgroup. Previous radiation exposure, most commonly in the form of radiotherapy for the treatment of another malignancy, did seem to predict the future development of thyroid cancer. Indeed, 4 of the 5 children in this series who received radiotherapy went on to develop papillary thyroid carcinoma. It is clear that this patient population requires diligent follow-up for the development of secondary thyroid malignancies, as has been well documented in Belarusian children after the Chernobyl disaster of 1986 [7].

Fine-needle aspiration cytology has been shown in several studies to have significant utility in preventing total thyroidectomy in adult patients with thyroid nodules [8]. Fine-needle aspiration cytology has been advocated in children as well, but not necessarily for these same reasons [9]. In pediatric patients, FNAC has generally been used to predict a more aggressive surgical approach from the outset

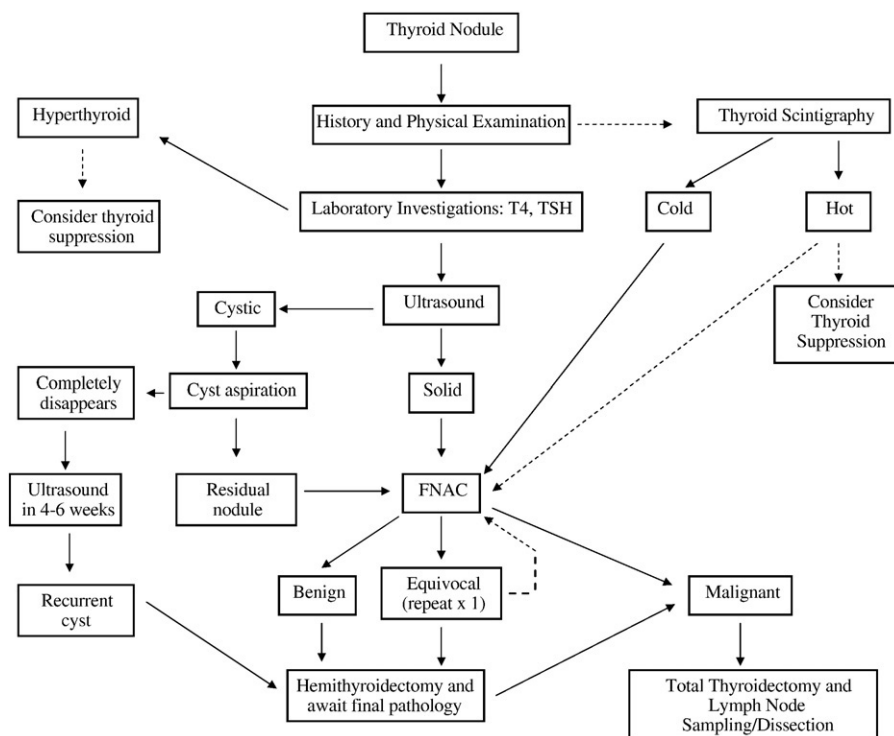


Fig. 2 Proposed algorithm for the evaluation of pediatric thyroid nodules. The dotted lines indicate an optional pathway of the algorithm that may be deemed appropriate for individual cases. Although a “benign” result from FNAC could warrant simple observation, based on the results of this study, hemithyroidectomy should be the next step.

(ie, total thyroidectomy), thus enabling the surgeon to appropriately counsel the patient and family [9]. In our series, less than 60% of all patients underwent FNAC. Determinate cytology was obtained in only 49% of patients who underwent the procedure. These rates of FNAC utilization are substantially lower than other published series [10,11]. Arguments against the routine use of FNAC in children have included the anatomical/physical limitation of the patient, the need for an experienced cytopathologist, the need for sedation in younger patients, and errors in sampling [9,12]. However, several studies have demonstrated a high sensitivity for the detection of malignant nodules through the use of FNAC [10,11,12]. For example, Corrias et al [10] demonstrated a 95% sensitivity of FNAC for the detection of malignant lesions in the 42 patients reviewed in their series. Recent reports have also demonstrated the utility of ultrasound-guided FNAC, where sampling error and complications may be minimized [13].

Until the accuracy, and in particular the sensitivity and negative predictive rate, of FNAC in children presenting with thyroid lesions can be further delineated, equivocal cytologic results from FNAC should still be regarded with caution. In situations where the clinical impression is unclear, pediatric patients may benefit from a hemithyroidectomy in order to obtain definitive pathologic confirmation of a benign lesion. If completion thyroidectomy is subsequently required, it may then be scheduled a few weeks later. Although this would require a second anesthetic, it would also circumvent the need for obligatory thyroid hormone replacement after the resection of a benign lesion. Most importantly, a staged procedure led to significantly fewer complications in our study population, particularly with regard to postoperative hypocalcemia and hoarseness. This interval of delay should not increase the likelihood of future metastasis or disseminated disease. Proceeding to total thyroidectomy in the absence of FNAC or other clinical corroboration may be too aggressive, thus leading to increased morbidity in our pediatric patients.

The results of the current study have highlighted a number of important issues in the management of children with thyroid nodules. First and foremost, the risk of malignancy in these lesions is high, and our aggressive surgical approach is likely warranted. However, preoperative investigations and imaging protocols are quite varied across the country. Risk factors predicting the presence of malignant lesions have been inconsistent. Fine-needle aspiration cytology has also been underused as a potentially effective tool to guide surgical treatment. To improve outcome and decrease morbidity, a staged approach may also be beneficial. What

is clear, however, is that the variability in practice patterns demonstrates a need to consolidate the peri-operative management of thyroid lesions in children. This may be possible through the prospective collection and analysis of variables linked to the outcome of these patients (family history, imaging, FNAC, etc). This analysis may then lend itself to the creation of a practice guideline that would be applicable to most pediatric patients with thyroid nodules. Our proposed algorithm for the management of pediatric thyroid nodules (Fig. 2) may provide a framework for future study. Collaborative efforts such as the CaPTN Study group can also play an important role in the development and implementation of these goals.

References

- [1] Niedziela M. Pathogenesis, diagnosis and management of thyroid nodules in children. *Endocr Relat Cancer* 2006;13:427-53.
- [2] Halac I, Zimmerman D. Thyroid nodules and cancers in children. *Endocrinol Metab Clin North Am* 2005;34:725-44.
- [3] Yip FW, Reeve TS, Poole AG, et al. Thyroid nodules in childhood and adolescence. *Aust N Z J Surg* 1994;64:676-8.
- [4] Lafferty AR, Batch JA. Thyroid nodules in childhood and adolescence—thirty years of experience. *J Pediatr Endocrinol Metab* 1997;10:479-86.
- [5] Skinner MA. Management of hereditary thyroid cancer in children. *Surg Oncol* 2003;12:101-4.
- [6] Niedziela M, Breborowicz D, Trejster E, et al. Hot nodules in children and adolescents in western Poland from 1996 to 2000: clinical analysis of 31 patients. *J Pediatr Endocrinol Metab* 2002;15:823-30.
- [7] Tronko MD, Howe GR, Bogdanova TI, et al. A cohort study of thyroid cancer and other thyroid diseases after the Chernobyl accident: thyroid cancer in Ukraine detected during first screening. *J Natl Cancer Inst* 2006;98:897-903.
- [8] Sakorafas GH, Peros G, Farley DR. Thyroid nodules: does the suspicion for malignancy really justify the increased thyroidectomy rates? *Surg Oncol* 2006;15:43-55.
- [9] Lugo-Vicente H, Ortiz VN, Irizarry H, et al. Pediatric thyroid nodules: management in the era of fine needle aspiration. *J Pediatr Surg* 1998;33:1302-5.
- [10] Corrias A, Einaudi S, Chiorboli E, et al. Accuracy of fine needle aspiration biopsy of thyroid nodules in detecting malignancy in childhood: comparison with conventional clinical, laboratory, and imaging approaches. *J Clin Endocrinol Metab* 2001;86:4644-8.
- [11] Amrikachi M, Ponder TB, Wheeler TM, et al. Thyroid fine-needle aspiration biopsy in children and adolescents: experience with 218 aspirates. *Diagn Cytopathol* 2005;32:189-92.
- [12] Chang SH, Joo M, Kim H. Fine needle aspiration biopsy of thyroid nodules in children and adolescents. *J Korean Med Sci* 2006;21:469-73.
- [13] Izquierdo R, Arekat MR, Knudson PE, et al. Comparison of palpation-guided versus ultrasound-guided fine-needle aspiration biopsies of thyroid nodules in an outpatient endocrinology practice. *Endocr Pract* 2006;12:609-14.