

# Anterior Intratumoural Chemotherapy: A Newer Modality of Treatment in Advanced Solid Tumours in Children

A.N. Gangopadhyay,<sup>1</sup> Rahi Rajeev,<sup>1</sup> S.P. Sharma,<sup>1</sup> Vijai D. Upadhyaya,<sup>1</sup> N.C. Arya,<sup>2</sup> Vijayendra Kumar<sup>1</sup> and S.C. Gopal,<sup>1</sup> Departments of <sup>1</sup>Paediatric Surgery and <sup>2</sup>Pathology, Institute of Medical Sciences, Banaras Hindu University, Varanasi, India.

**OBJECTIVE:** Advanced and inoperable solid tumours in children have high mortality despite aggressive multimodal treatment. Intravenous chemotherapy is abandoned at times because of systemic toxicity. This study investigated intratumoural chemotherapy and compared it with intravenous chemotherapy.

**METHODS:** Forty children with advanced inoperable solid tumours (Wilms' tumour and neuroblastoma) were randomly allocated into two groups of 20. Group A was given intratumoural chemotherapy and group B was given intravenous chemotherapy. Both groups were compared for reduction in tumour size and volume, tumour resectability, histopathological changes and drug side effects.

**RESULTS:** Intratumoural chemotherapy was superior to intravenous chemotherapy in terms of reducing tumour size and volume (63% in group A vs. 22% in group B). The resectability was 70% in the intratumoural group compared with 40% in the intravenous group. The overall good histopathological response was 71% in group A as opposed to 0% in group B. Moreover, the incidence and severity of drug side effects and morbidity were less with intratumoural chemotherapy. Mortality was also low in group A (5%) compared to group B (20%).

**CONCLUSION:** Intratumoural chemotherapy can be offered as an effective and safe alternative treatment modality for advanced and inoperable Wilms' tumour and neuroblastoma. [*Asian J Surg* 2008; 31(4):225-9]

**Key Words:** advanced solid tumours, intratumoural chemotherapy, intravenous chemotherapy, paediatric tumours

## Introduction

Advanced and inoperable solid tumours in children have a high mortality rate despite aggressive multimodal treatment. Most solid tumours in children under 15 years of age are neuroblastoma, Wilms' tumour, lymphoma and rhabdomyosarcoma. These account for 28.1% of all child cancers and their incidence is 7.3%, 6.1%, 11.3% and 3.4%, respectively.<sup>1,2</sup> Since apart from lymphoma, Wilms' tumour

and neuroblastoma comprise > 80% of all solid childhood malignancies, we concentrated our study only on Wilms' tumour and neuroblastoma.

In our study, due to their illiteracy and lower socio-economic status, patients with Wilms' tumour and neuroblastoma tended to present at an advanced stage and were inoperable at the time of initial presentation. Although there have been many advances with the collaboration of paediatric oncologists, surgeons and radiotherapists, the

Address correspondence and reprint requests to Professor A.N. Gangopadhyay, Department of Paediatric Surgery, Institute of Medical Sciences, Banaras Hindu University, 161 Ganeshpuri Suswahi, Varanasi 221005, India.  
E-mail: gangulybhu@rediffmail.com • Date of acceptance: 5 August 2008

prognosis for advanced solid malignancies in children remains poor.<sup>3-5</sup> Some improvement in survival has been noted by alternating effective chemotherapeutic agents to overcome or prevent resistance, and by continuous infusion rather than bolus administration of drugs.<sup>6,7</sup> Alternative routes of administration of chemotherapeutic agents have been tried for advanced solid tumours, mostly for palliation. In 1976, intra-arterial transcatheter occlusion of abdominal tumours was tried by Goldstein et al.<sup>8</sup> Intra-arterial chemotherapy has been tried for hepatocellular carcinoma, and advanced pancreatic, breast and liver metastases from colorectal carcinoma.<sup>9-17</sup> Intraperitoneal chemotherapy has also shown promising antitumour efficacy against ovarian carcinoma, peritoneal carcinomatosis and advanced gastric carcinoma.<sup>18-20</sup> However, all these studies were restricted to adults. Livraghi et al<sup>21,22</sup> reported fine needle percutaneous intratumoural chemotherapy under ultrasound guidance in 12 selected adult patients with tumours that did not respond to conventional treatment. Partial or total pain control, disease stability and response were observed in 60% of patients. They concluded that intratumoural chemotherapy may be an alternative treatment for tumours that are unresponsive to conventional chemotherapy.

An extensive literature search failed to find any studies on intratumoural chemotherapy in paediatric solid tumours. Therefore, our study was a pilot study of intratumoural chemotherapy in advanced solid tumours in children.

## Methods

The study was conducted in the Department of Paediatric Surgery with cooperation from the Department of Radiology and the Department of Pathology at University Hospital, Varanasi. The period of study was from July 2000 to June 2004. Forty patients with advanced inoperable solid tumours, nephroblastoma and neuroblastoma, were randomly allocated into two groups (A and B) of 20 patients, after confirming diagnosis by fine needle aspiration cytology. Group A consisted of 13 patients with Wilms' tumour and seven with neuroblastoma. Patients were treated with intratumoural vincristine (1.5 mg/m<sup>2</sup>), actinomycin D (45 µg/kg) and adriamycin (50 mg/m<sup>2</sup>) through a 26 G spinal needle under aseptic conditions and ultrasound guidance, at the same doses and schedule as used for standard systemic chemotherapy. Adriamycin

and actinomycin D were given as a single dose while vincristine was given weekly for 6 weeks. An injection of hyaluronidase was added to the drugs to enhance their local distribution. Group B consisted of 14 patients with Wilms' tumour and six with neuroblastoma. Patients were treated with intravenous chemotherapy with the same doses and schedule as for group A.

All patients were evaluated by two senior consultants by clinical examination, sonography and computed tomography to establish the inoperability of the tumour. The tumour volume under ultrasound guidance was calculated by the formula: 0.523 × the product of the three dimensions of the tumour. Patients were evaluated before, during and after chemotherapy as per the set pro forma. The symptoms and drug side effects in both groups were noted. Supportive therapy was given in the form of whole blood, platelet concentrate and fresh frozen plasma as and when required.

After removal of the tumour, both groups received intravenous chemotherapy as per standard schedule (NWTS protocol). Ten slides from each specimen were taken for detailed microscopic examination, to compare various histopathological changes that occurred following chemotherapy.

Z value was calculated, using the following equation, for statistical analysis.

$$Z = \frac{P_1 - P_2}{\sqrt{P_1 q_1/n_1 + P_2 q_2/n_2}}$$

where P<sub>1</sub> is the proportion in the first sample, P<sub>2</sub> is the proportion in the second sample, n<sub>1</sub> is the size of the first sample, n<sub>2</sub> is the size of the second sample, q<sub>1</sub> = 1 - P<sub>1</sub> and q<sub>2</sub> = 1 - P<sub>2</sub>. If Z was > 1.96, then it was significant at 5% (p < 0.05).

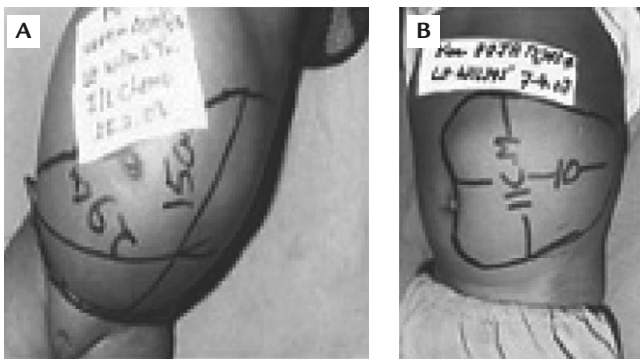
## Results

### *Reduction in tumour size and volume*

Intratumoural chemotherapy was superior to intravenous chemotherapy in terms of reducing tumour size (Figure 1) and volume, and down-staging the tumour to allow resectability.

### *Resectability and histological response*

The resected specimens were examined histopathologically and divided into three groups on the basis of Zuppan criteria.<sup>23</sup> Type I, good response: microscopic examination showed extensive necrosis, focal fibrosis and inflammatory



**Figure 1.** A case of Wilms' tumour in the intratumoural chemotherapy group that was reduced in size after treatment.

cells, which were mainly eosinophilic. There was also haemorrhage, hyaline degeneration and soft tissue. No malignant cells were detected in any tissue sections. Type II, partial response: microscopy revealed predominance of atrophic dilated glands with scanty blastemal/tumour cells. Angiomatous malformations were also seen in some sections. Type III, non responders: focal areas of mainly blastemal/tumour cells, with few glands separated by dense fibrocollagenous tissue. There were no inflammatory cells, necrosis or haemorrhage.

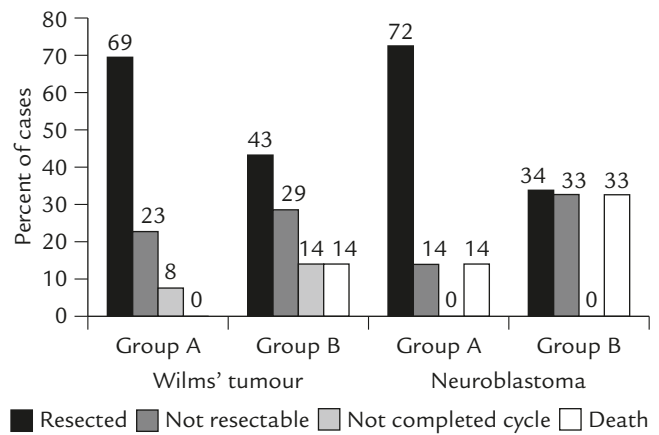
In nine out of 13 patients (69%) in group A with Wilms' tumour, surgical resection was possible after intratumoural chemotherapy. Six (67%) of these showed a good response according to histopathological criteria, while two (22%) had a partial response and the remaining patient (11%) had no response. In five out of seven patients (72%) in group A with neuroblastoma, surgical resection was possible after completion of intratumoural chemotherapy. Four of these (80%) responded well and one patient (20%) had a partial response (Figures 2 and 3). Overall, the good response rate according to histopathological criteria was 71% in group A and 0% in group B (Figure 4). The Z value of 5.90 was statistically significant.

*Side effects of chemotherapy*

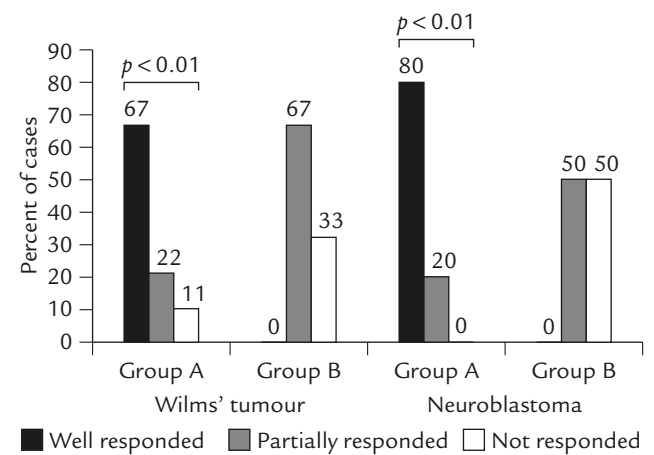
The incidence and severity of side effects was low in group A. Moreover, although chemotherapy can lead to severe anaemia and pancytopenia, the requirement for blood transfusion was also low in group A in comparison to group B (Table).

**Discussion**

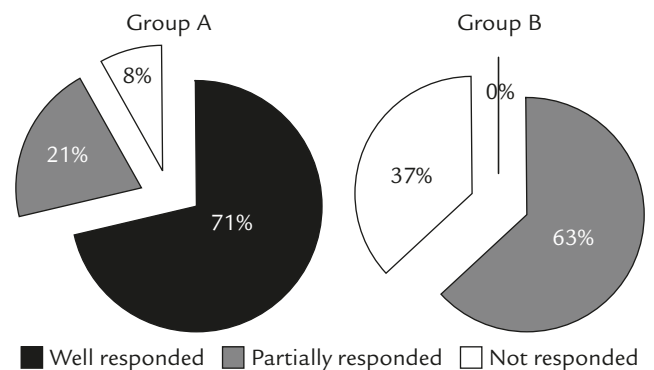
Advanced and inoperable solid tumours in children are difficult to manage in spite of advances in cancer research,



**Figure 2.** Resectability and outcome after two modalities of chemotherapy.



**Figure 3.** Histological response to two modalities of chemotherapy.



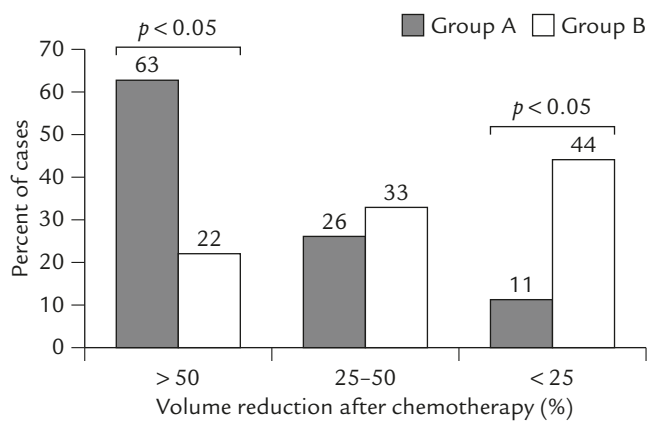
**Figure 4.** Overall histopathological response to two modalities of chemotherapy.

mainly because advanced disease leads to a poor general condition and intolerance of multimodal therapy. The International Society of Paediatric Oncology (SIOP) has promoted the use of preoperative chemotherapy with or without radiotherapy to increase tumour resectability and to minimize surgical complications.<sup>24,25</sup> The response to

**Table.** Side effects of chemotherapeutic drugs

	Wilms' tumour*		Z (p)	Neuroblastoma*		Z (p)
	Group A	Group B		Group A	Group B	
Nausea	4 (31)	10 (71)	2.307 (<0.05)	3 (43)	4 (67)	0.888
Leucopenia (<5,000/mm <sup>3</sup> )	1 (8)	6 (43)	2.378 (<0.05)	2 (29)	2 (33)	0.183
Alopecia	2 (15)	9 (64)	3.037 (<0.01)	4 (57)	4 (67)	0.358
Local pain	2 (15)	-	1.54	1 (14)	-	1.083
Colitis	1 (8)	-	0.94	1 (14)	-	1.083
Sterile pus	1 (8)	-	1.085	-	-	-
Fever	3 (23)	5 (36)	0.728	1 (14)	3 (50)	1.457
Loss of appetite	-	2 (14)	1.521	-	1 (17)	1.099
Blood transfusion	2 (15)	6 (43)	1.683	3 (43)	5 (83)	1.676
Stomatitis/mouth ulcer + skin rashes	2 (15)	5 (36)	1.261	-	2 (33)	1.734

\*Data presented as n (%).



**Figure 5.** Volume reduction after chemotherapy in both Wilms' tumour and neuroblastoma.

conventional intravenous chemotherapy is varied due to systemic spread of disease and poor tolerance of already malnourished patients leading to postponement of chemotherapy in between.

In our study, intratumoural chemotherapy produced better and earlier tumour regression than intravenous chemotherapy, measured both by clinical examination (tumour size) and ultrasonography (tumour volume). This finding was statistically significant in patients who had responded to chemotherapy (> 50% reduction in tumour volume) (Figure 5).

Tumours in 70% of patients in group A were successfully excised after one course (6 weeks) of intratumoural chemotherapy in comparison to only 40% in the intravenous chemotherapy group (group B). Unlike patients with intravenous chemotherapy, those who received intratumoural chemotherapy did not have much adhesion

with any of the surrounding tissue, which suggested that the drugs did not extravasate from the tumour, and it was a safe method. It was observed during surgery that neovascularization and oedema were significantly less in the intratumoural group as compared with the intravenous group, which may have been caused by the high concentration of chemotherapeutic drugs acting on target tumour cells.

Seven patients in group A who presented with metastasis, e.g. tumour thrombus in the inferior vena cava, or secondary deposits in the supraclavicular or para-aortic lymph nodes or liver, also responded well to treatment, with disappearance of metastatic deposits (clinically, radiologically and histologically) at the end of six cycles of chemotherapy. Thus, intratumoural chemotherapy acted both locally and systemically.

One patient with advanced neuroblastoma in group A died during intratumoural chemotherapy because of extensive primary disease. However, this patient had started responding satisfactorily in terms of tumour regression. The mortality was 5% in group A as compared to 20% in group B, which was a statistically significant difference. None of our patients treated with intratumoural chemotherapy developed any metastasis during therapy, which suggests that its systemic effect resulted from a sustained release of drugs from the tumour to the circulation.

In terms of histopathology, 71% of patients in the intratumoural chemotherapy group (A) responded well to treatment, compared with none in the intravenous chemotherapy group (B). However, 21% in group A and 63% in group B showed a partial response. Eight percent

of patients in group A showed no response, compared with 37% in group B. Histopathological response was highly significant in those who responded well to treatment (Figure 2).

The present study on intratumoural chemotherapy in advanced solid tumours in children was conducted as a pilot study and no reference data are available in the literature. In the present study, a fixed regimen of chemotherapy that comprised vincristine, adriamycin and actinomycin D was given intratumourally to patients with two types of advanced-stage tumours, and the results were assessed clinically, sonographically and histopathologically. Although intravenous chemotherapy has been the conventional form of treatment for advanced stage tumours, it is toxic in children because of the high required doses, and mostly leads to abandonment of therapy. Intratumoural chemotherapy is superior to intravenous chemotherapy in terms of better and earlier tumour regression, minimal side effects, better tumour resectability and a good histopathological response.

This pilot study lays the foundation for treating inoperable solid tumours in children with neoadjuvant intratumoural chemotherapy, and proves its superiority over the currently used intravenous chemotherapy.

## References

- Parker SL, Tong T, Bolden S, et al. Cancer statistics. 1996. *Cancer J Clin* 1996;65:5-27.
- Gurney JG, Severson RK, Davis S, et al. Incidence of cancer in children in the United States. *Cancer* 1995;75:2186-95.
- Schwenn MR, Blattner SR, Lynch E, et al. Hic-Com: a 2 month intensive chemotherapy regimen for children with stage III and IV Burkitt's lymphoma and B-cell acute lymphoblastic leukemia. *J Clin Oncol* 1991;9:133-8.
- Cheung NK, Heller G. Chemotherapy dose intensity correlates strongly with response, median survival and median progression free survival in metastatic neuroblastoma. *J Clin Oncol* 1991; 9:1050-8.
- Antman K, Ayash L, Elias A. A phase II study of high dose cyclophosphamide, thiotepa and carboplatin with autologous marrow support in women with measurable advanced breast cancer responding to standard therapy. *J Clin Oncol* 1992;10: 102-10.
- Grier H, Krailo M, Link M, et al. A children's cancer group and paediatric oncology group report. *J Clin Oncol* 1994;13(Suppl): 421-3.
- Clark PI, Slevin ML, Joel SP. A randomized trial of two etoposide schedules in small cell lung cancer. *J Clin Oncol* 1994;12:1427-35.
- Goldstein HM, Wallace S, Anderson JH, et al. Transcatheter occlusion of abdominal tumors. *Radiology* 1976;120:539-45.
- Horiuchi H, Ishikawa H, Haraki M, et al. Intra-arterial chemotherapy with gemcitabine for unresectable pancreatic cancer. *Gan To Kagaku Ryoho* 2002;29:2065-9.
- Ando E, Tanaka M, Yamashita F, et al. Hepatic arterial infusion chemotherapy for advanced hepatocellular carcinoma with portal vein tumor thrombosis: analysis of 48 cases. *Cancer* 2002;95:588-95.
- Takalsuka Y, Yayoi K, Kobayashi T, et al. Neoadjuvant intraarterial chemotherapy in locally advanced breast cancer. A prospective randomized trial. *Jpn J Clin Oncol* 1994;24:20-5.
- Kemeny N, Conti JA, Cohen A, et al. Phase II study of hepatic arterial floxuridine, leucovorin and dexamethasone for unresectable liver metastases from colorectal carcinoma. *J Clin Oncol* 1994;12:2288-95.
- Court WS, Order SE, Siagel JA, et al. Remission and survival following monthly intra arterial cisplatin in nonresectable hepatoma. *Cancer Invest* 2002;50:613-25.
- Chuang VP, Wallace S. Hepatic artery embolization in the treatment of hepatic neoplasms. *Radiology* 1981;140:51-8.
- Ymado R, Sato M, Kwabata M, et al. Hepatic artery embolization in 120 patients with unresectable hepatoma. *Radiology* 1983;148: 397-401.
- Kajanti M, Rissanen P, Virkkunen P, et al. Regional intra-arterial infusion of cisplatin in primary hepatocellular carcinoma: a phase II study. *Cancer* 1986;58:2386-8.
- Sangro B, Rios R, Bilbao I, et al. Efficacy and toxicity of intraarterial cisplatin and etoposide for advanced hepatocellular carcinoma. *Oncology* 2002;62:293-8.
- Zylberberg B, Dormont D, Ylberberg S, et al. Outcome of patients treated with intraperitoneal immunochemotherapy for ovarian cancer. *Contracept Fertil Sex* 1998;26:790-9.
- Hirose K, Katayama K, Lida A, et al. Efficacy of continuous hyperthermic peritoneal perfusion for prophylaxis and treatment of peritoneal metastasis of advanced gastric cancer. Evaluation by multivariate regression analysis. *Oncology* 1999;57:106-14.
- Yu W, Whang I, Suh I, et al. Prospective randomized trial of early postoperative intraperitoneal chemotherapy as an adjunct to resectable gastric cancer. *Ann Surg* 1998;228:347-54.
- Livraghi T, Ravetto C, Solbiati L, et al. Percutaneous interstitial chemotherapy of a small hepatocellular carcinoma under ultrasound guidance. *Tumori* 1986;72:525-7.
- Livraghi T, Bajetta E, Matricardi L, et al. Fine needle percutaneous intratumoral chemotherapy under ultrasound guidance: a feasibility study. *Tumori* 1986;72:81-7.
- Zuppan CW, Beckwith B, Weeks DA, et al. The effect of preoperative therapy of the histologic features of Wilms' tumor. *Cancer* 1991;68:385-94.
- Godzinski J, Tournade MF, de Kraker J, et al. Rarity of surgical complications after post chemotherapy nephrectomy for nephroblastoma. Experience of trial and study-SIOP-9. *Eur J Paed Surg* 1998;8:81-7.
- Godzinski J, Tournade MF, de Kraker J, et al. The role of preoperative chemo in the treatment of nephroblastoma: the SIOP experience. *Semin Urol Oncol* 1998;17:28-32.