

Magnetic Resonance Cholangiography for the Diagnosis of Biliary Atresia

By Seok Joo Han, Myung-Joon Kim, Airi Han, Ki Sup Chung, Choon Sik Yoon,
Dojoong Kim, and Eui Ho Hwang
Seoul, Korea

Purpose: The aim of this study was to evaluate the usefulness of magnetic resonance cholangiography (MRC) for the diagnosis of biliary atresia in infantile cholestatic jaundice.

Methods: Forty-seven consecutive infants with cholestatic jaundice underwent single-shot MRC. The diagnosis of biliary atresia was made by MRC based on the nonvisualization of extrahepatic bile ducts and excluded on the basis of the complete visualization of extrahepatic bile ducts. The final diagnosis of biliary atresia (BA group, n = 23) or nonbiliary atresia (NBA group, n = 24) was established by operation or clinical follow-up until the jaundice resolved.

Results: The extrahepatic bile ducts including the gallbladder, the cystic duct, the common bile duct, and the common hepatic duct were visualized in 23 of the 24 infants of the

NBA group. The extrahepatic bile ducts, except the gallbladder, were not depicted in any infant of the BA group. MRC had an accuracy of 98%, sensitivity of 100% and specificity of 96%, for diagnosis of biliary atresia as the cause of infantile cholestatic jaundice.

Conclusions: MRC is a very reliable noninvasive imaging modality for the diagnosis of biliary atresia. In infants with cholestatic jaundice and considered for exploratory laparotomy, MRC is recommended to avoid unnecessary surgery. *J Pediatr Surg 37:599-604. Copyright 2002, Elsevier Science (USA). All rights reserved.*

INDEX WORDS: Biliary atresia, cholestatic jaundice, magnetic resonance cholangiography.

THE ACCURATE and prompt differentiation of biliary atresia from other causes of cholestatic jaundice in the infants is important because these patients must undergo surgery as soon as possible to improve the surgical outcome.^{1,2} Despite many attempts to differentiate biliary atresia from other causes of infantile cholestatic jaundice, no single test or imaging modality had reliably defined the causes of cholestatic jaundice in the infants.

Magnetic resonance cholangiography (MRC) permits noninvasive evaluation of the biliary tree in infants and children.^{3,4} It was reported that biliary atresia could be excluded if the extrahepatic bile duct is visualized completely by MRC.⁵ In a preliminary study, we found that MRC could depict the extrahepatic bile duct in 9 infants with neonatal hepatitis, whereas the extrahepatic bile ducts could not be visualized in 12 patients with biliary atresia.⁶

The purpose of this study was to evaluate the usefulness of MRC for the diagnosis of biliary atresia as a cause of infantile cholestatic jaundice in a large series of infants.

MATERIALS AND METHODS

From January 1998 to October 2000, MRC was performed prospectively on selected patients that presented with cholestatic jaundice and acholic stool. The patients were excluded from this study if the abdominal ultrasonography (US) or diisopropyliminodiacetic acid (technetium 99m DISIDA) hepatobiliary scan eliminated the likelihood

of the diagnosis of biliary atresia. None of the patients underwent liver biopsy preoperatively.

A detailed MRC technique for cholestatic jaundice in infants has been published previously.⁶ Imaging parameters were optimized to detect the extrahepatic bile duct and avoid the extrahepatic fluid signals. MRC was obtained by 1 pediatric radiologist who had enough MR imaging experience. He also made all radiologic diagnoses of MRC prospectively. A diagnosis of biliary atresia was excluded by MRC based on the visualization of both the common bile duct and the common hepatic duct, and the diagnosis of biliary atresia was made on the basis of the nonvisualization of either the common bile duct or the common hepatic duct. All MR images also were reviewed independently by 2 pediatric radiologists with no experience with MRC for infantile cholestatic jaundice, and they were blinded to both the clinical history and the results of other tests. The degree of bile duct visualization and periportal thickening were scored. Discrepancies were resolved by consensus.

The diagnosis of biliary atresia or other causes of cholestasis was established at surgery by operative cholangiography and liver biopsy or was made clinically by the imaging findings and clinical follow-up until the jaundice resolved.

Patients were divided into 2 groups on the basis of the final diagnosis

From the Departments of Pediatric Surgery, Diagnostic Radiology, and Pediatrics, Yonsei University College of Medicine, Seoul, Korea.

Presented at the 34th Annual Meeting of the Pacific Association of Pediatric Surgeons, Kyoto, Japan, April 4-8, 2001.

Address reprint requests to Seok Joo Han, MD, Department of Pediatric Surgery, Yonsei University College of Medicine, Shinchondong 134, Seodaemun-ku, Seoul 120-752, Korea.

Copyright 2002, Elsevier Science (USA). All rights reserved.

0022-3468/02/3704-0008\$35.00/0

doi:10.1053/jpsu.2002.31617

Table 1. Demographic Characteristics and Final Diagnosis in Infantile Cholestatic Jaundice (n = 47)

	BA Group (n = 23)	NBA Group (n = 24)
Gender (% , P = .052)		
Male	6 (26)	13 (54)
Female	17 (74)	11 (46)
Age at MR cholangiography (d, P = .556)	65.9 (range, 15-210)	71.5 (range, 21-150)
Final diagnosis	Type of biliary atresia ⁷	Neonatal hepatitis 20 (84%)
	Type I 1 (4%)	TPN-associated cholestasis 2 (8%)
	Type II 1 (4%)	Sclerosing cholangitis 1 (4%)
	Type III 21 (92%)	Spontaneous CHD perforation 1 (4%)

Abbreviations: TPN, total parenteral nutrition; CHD, common hepatic duct.

(BA group, biliary atresia group; NBA group, non-biliary atresia group). The Student's *t* test was used to compare the ages of the 2 groups, and the Mann-Whitney U test was used to compare the sexes in the 2 groups. Student's *t* test was used to evaluate the statistical significance of MR image visualization scores. A *P* value of less than .05 was considered to indicate statistical significance.

RESULTS

Forty-seven patients with infantile cholestatic jaundice were included in this study. The diagnosis was established in 27 patients at surgery (23 in the BA group and 4 in NBA group) and in 20 patients without surgery (20 in NBA group).

Demographic Characteristics and Final Diagnosis

Table 1 lists the demographic characteristics and diagnoses of 47 infants with cholestatic jaundice included in this study. No significant statistical difference was evident in the gender and the age.

MR Cholangiographic Findings and Reliability

The extrahepatic bile ducts including the gallbladder, the cystic duct, the common bile duct, the common

hepatic duct, and the right and left intrahepatic ducts were visualized in 23 of the 24 infants of the NBA group in which the correct diagnosis of non-biliary atresia was made by MRC (Figs 1 and 2A). The second-order intrahepatic ducts were visualized in 7 patients (29%) in the NBA group (Fig 2A). MRC of 1 case in the NBA group, performed at the beginning of this study, was not interpreted correctly as non-biliary atresia because of poor image resolution and the inexperience of the radiologist. The extrahepatic bile ducts, except the gallbladder, were not depicted in any infant of the BA group, in which a correct diagnosis of biliary atresia was made by MRC (Figs 1 and 2B). In the single patient with type I biliary atresia, MRC failed to depict the extremely hypoplastic intrahepatic ductules confirmed at operative cholangiography (Fig 3). In the one patient with type II biliary atresia, MRC failed to show a hypoplastic common bile duct, which was visible at operative cholangiography. Periportal thickening, as defined by the presence of an increased signal intensity on the T₂-weighted conventional MR images, was seen in 22 patients (96%) of the BA group and in 10 patients (42%) of the NBA group

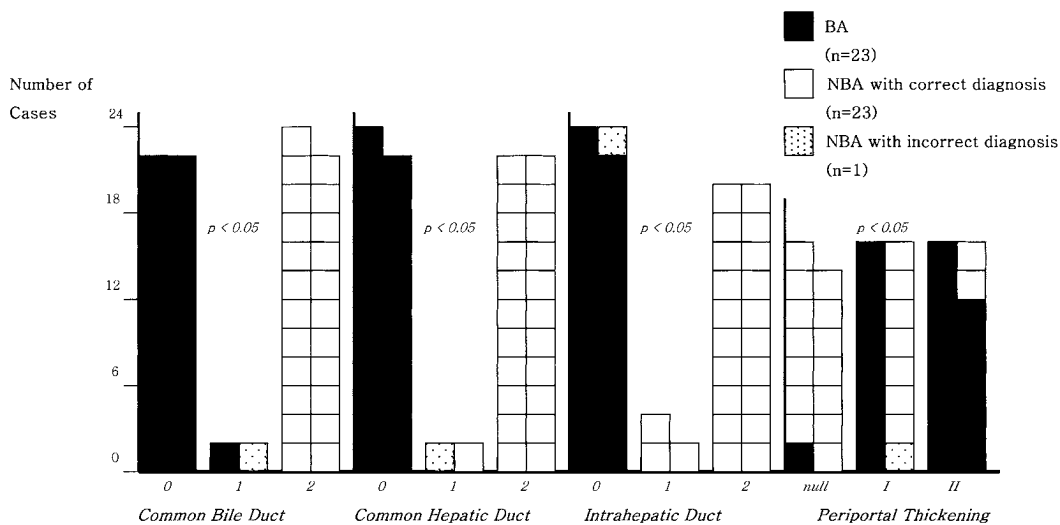


Fig 1. Score of magnetic resonance cholangiographic findings in infantile cholestatic jaundice (n = 47). BA, biliary atresia in final diagnosis; NBA, non-biliary atresia in final diagnosis; 0, no visualization; 1, uncertain visualization; 2, definite visualization; null, no periportal thickening; I, periportal thickening less than the diameter of portal vein; II, periportal thickening ≥ diameter of portal vein.

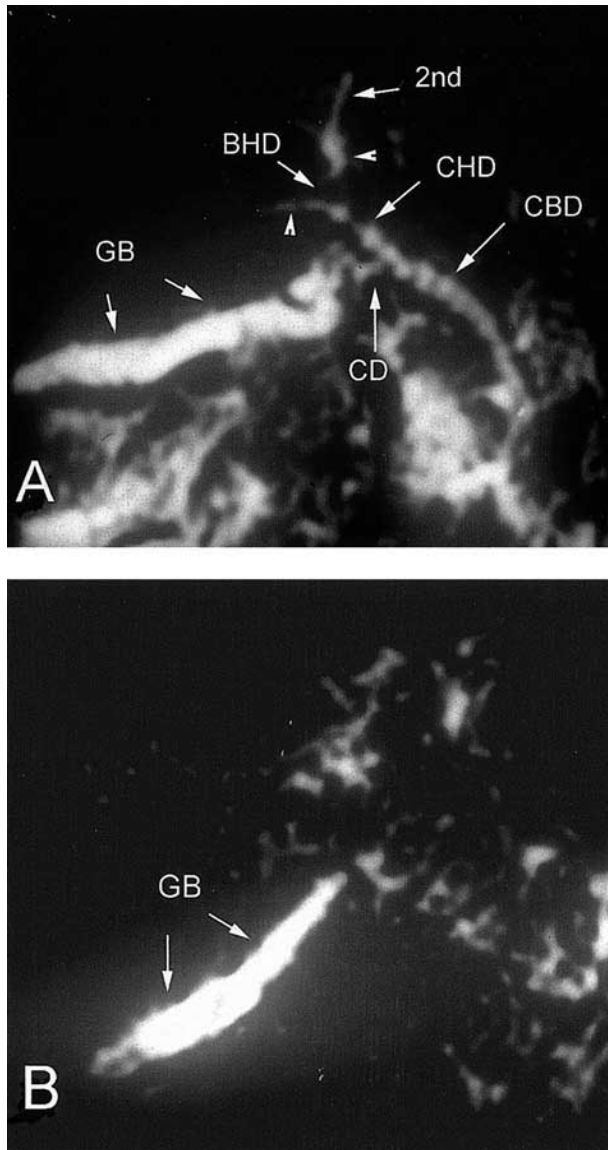


Fig 2. (A) Magnetic resonance cholangiography obtained in a 69-day-old girl with neonatal hepatitis shows gallbladder (GB), cystic duct (CD), common bile duct (CBD), common hepatic duct (CHD), bifurcation of intrahepatic ducts (BHD), right and left intrahepatic ducts (arrowheads) and second branch of left intrahepatic duct (2nd). (B) Magnetic resonance cholangiography obtained in a 64-day-old boy with biliary atresia does not show any extrahepatic bile ducts except gallbladder (GB).

(Figs 1 and 4), which represented a statistically significant difference between the 2 groups.

In the diagnosis of biliary atresia, MRC resulted in a diagnostic accuracy of 98% with a sensitivity of 100%, a specificity of 96%, a positive predictive value of 96%, and a negative predictive value of 100% (Table 2).

DISCUSSION

Early differentiation between biliary atresia and neonatal hepatitis is important because the prognosis after

hepatic portoenterostomy is inversely related to the infant's age at operation.⁸ However, conventional investigations to differentiate neonatal hepatitis from biliary atresia, on many occasions, cannot establish a definite diagnosis before operation; surgical exploration then is necessary.

Abdominal US is the best initial noninvasive radiologic investigation for cholestatic jaundice in the infants

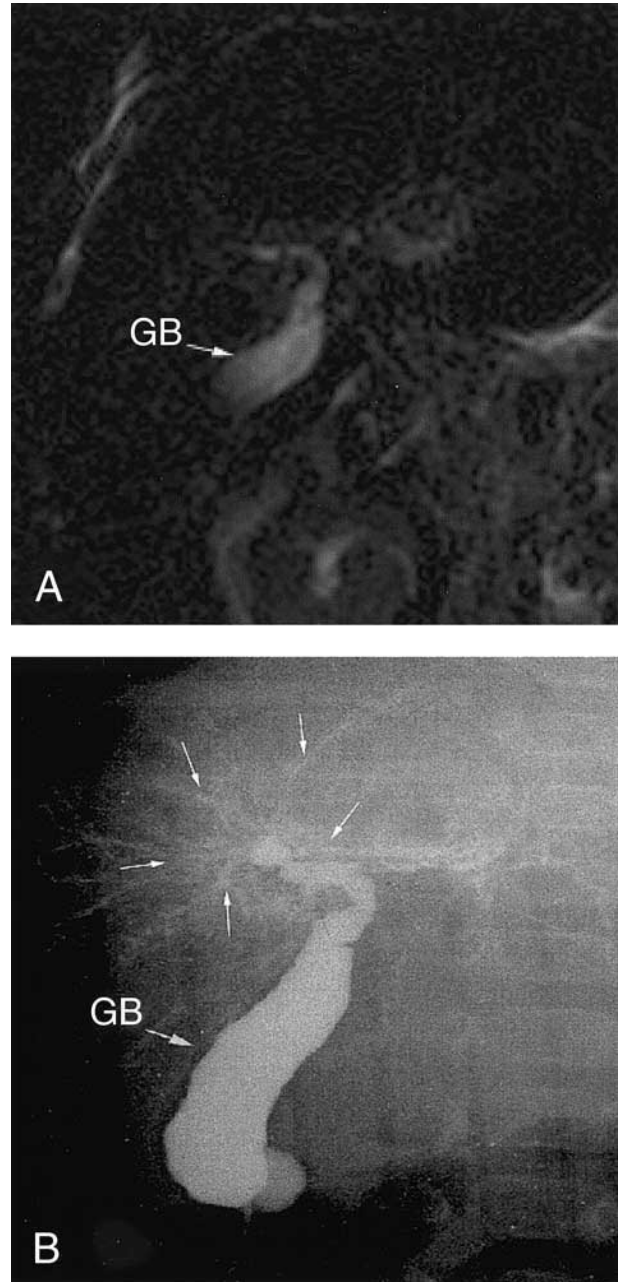


Fig 3. In type I biliary atresia,⁷ magnetic resonance cholangiography (A) fails to depict the extremely hypoplastic intrahepatic ductules (white arrows), which are visible at operative cholangiography (B). GB, gallbladder.

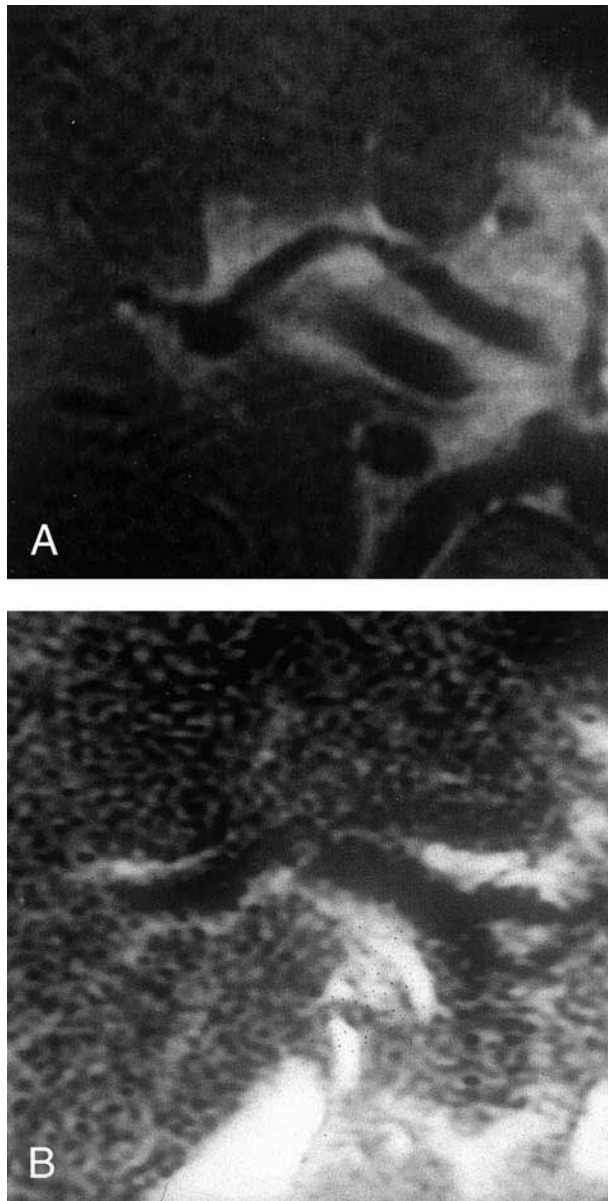


Fig 4. (A) Magnetic resonance cholangiography shows grade II periportal thickening in 57-day-old girl with biliary atresia. (B) Magnetic resonance cholangiography shows grade I periportal thickening in 63-day-old girl of neonatal hepatitis.

but cannot reliably identify all causes.⁹ Hepatobiliary scintigraphy has very high sensitivity for the diagnosis of biliary atresia, but it has low specificity and requires cautious interpretation.¹⁰ Although histologic examination of the liver is a reliable test for the differentiation of cholestatic jaundice in infants,¹¹ it is invasive and takes a long time to get an interpretation. Moreover, there are some histologic similarities between biliary atresia and neonatal hepatitis.¹² Endoscopic retrograde cholangiopancreatography (ERCP)¹³⁻¹⁵ and percutaneous transhepatic cholangiography^{16,17} are invasive, not always

successful in small infants, and often need general anesthesia for their performance. Laparoscopic-guided cholangiography has been reported as a helpful modality for the evaluation of infants with cholestatic jaundice.¹⁸ However, it also is invasive and requires a general anesthesia and an experienced team that can visualize the biliary system of small infants safely. The ideal diagnostic tool for the differentiation of cholestatic jaundice in the infants should be accurate, reliable, noninvasive, and easy to use.

MRC currently is an important noninvasive technique for the complete visualization of the biliary system in adults. It also is a useful tool in the evaluation of hepatobiliary diseases in infants and children.^{4,6,19-21} Previous studies have suggested that MRC in small infants can provide images with a resolution enough that nondilated extrahepatic bile ducts can be depicted clearly.^{4,6,20-22} Guibaud et al²⁰ reported a preliminary result and suggested that biliary atresia can be excluded if the complete extrahepatic bile ducts can be identified on MRC. Jaw et al²² reported that MRC performed in 16 jaundiced infants (6 biliary atresia and 10 non-biliary atresia) was 100% accurate in excluding biliary atresia as the cause of infantile cholestatic jaundice and suggested that it may replace diagnostic laparotomy and operative cholangiography in jaundiced infants in whom no excretion of bile is evident on hepatic scintigraphy. However, they believed that more clinical investigatory studies were required to establish the accuracy of MR cholangiography in terms of excluding biliary atresia. We performed MRC prospectively for the evaluation of cholestatic jaundice in a large series that resulted in very high accuracy.

In this study, all extrahepatic bile ducts were well visualized in the 23 patients in NBA group (Fig 1A). Biliary atresia could, therefore, be excluded and laparotomy avoided. The extrahepatic bile ducts, except the gallbladder, were not seen in any case in the BA group; the diagnosis of biliary atresia could be made with MRC (Fig 1B).

The MRC of infants with type I and II of biliary atresia in this study did not show the very thin but patent bile

Table 2. Validity and Reliability of Magnetic Resonance Cholangiography for Diagnosis of Biliary Atresia

Fn Dx	MRC Dx		
	BA	NBA	Total
BA (n = 23)	23	0	23
NBA (n = 24)	1	23	24
Total	24	23	47

NOTE. Accuracy, 98%; sensitivity, 100%; specificity, 96%; positive predictive value, 96%; and negative predictive value, 100% for diagnosis of biliary atresia.

Abbreviations: BA, biliary atresia; NBA, non-biliary atresia; MRC Dx, MR cholangiographic diagnosis; Fn Dx, final diagnosis.

ducts (intrahepatic bile ducts in type I and common bile duct in type II) that were seen using the operative cholangiography (Fig 3). It has been reported that inadequate water and extremely small caliber make the hypoplastic bile duct invisible in MRC.²² Guibaud et al²⁰ have reported a false-positive diagnosis of biliary atresia in an infant with sclerosing cholangitis, in whom MRC could not show the extrahepatic bile duct because of its small caliber. However, the MRC in our case of sclerosing cholangitis showed the small extrahepatic bile duct. In the future, visualization of a very thin bile duct, such as that illustrated in Fig 3, might be possible with further improvements in the resolution of MRC and enable the certain classification of the type of biliary atresia by MRC.

Although it has been reported that a small gallbladder by MRC can be considered highly suggestive of biliary atresia,²² and almost all of the MRC in our study also showed the gallbladder in the BA group, we did not measure the gallbladder size at MRC because the abdominal US can measure gallbladder size more accurately. However, in our study, the size of the gallbladder with biliary atresia at MRC seemed to be significantly smaller than in infants with neonatal hepatitis.

Periportal thickening in the MR image seems to represent periportal fibrosis on histologic examination²³ and increased sonographic echo in the periportal area.²⁴ The degree of periportal thickening in our study was significantly greater in the BA group than in NBA group. Although other investigators^{20,22} have reported that periportal thickening on the MRC was not seen in non-

biliary atresia; 10 of 23 patients with non-biliary atresia in our study had mild to moderate degrees of periportal thickening by MRC. We believe that this periportal thickening in patients without biliary atresia might correspond to histologic changes (fibrosis, inflammation, or edema) around the portal tract in the late stage of liver disease. Periportal thickening may be a helpful MR cholangiographic finding in the diagnosis of biliary atresia, but it is not pathognomonic.

Technetium 99m DISIDA hepatobiliary scans were omitted from the evaluation of cholestatic jaundice of infants during the later period of this study because we believed that it probably was unnecessary in this era of highly reliable MRC. However, there are pitfalls associated with this thinking. MRC is more expensive than hepatobiliary scintigraphy and not available in all hospitals. Hepatobiliary scintigraphy reliably can exclude the diagnosis of biliary atresia by showing the drainage of radiotracer into the small bowel. One of the vulnerable points of MRC is that it does not show the bile flow itself as does hepatobiliary scintigraphy or ERCP. We think that abdominal US and hepatobiliary scintigraphy still should be included in the routine imaging examination of infants with cholestatic jaundice.

MRC, which can be performed noninvasively, is a very reliable imaging study for the diagnosis of biliary atresia and could help in early referrals from pediatricians who may spend much time seeking nonsurgical causes for jaundice in infants. Preoperative MRC is highly recommended to avoid unnecessary surgery in infants with cholestatic jaundice.

REFERENCES

- Balistreri WF, Grand R, Hoofnagle JH, et al: Biliary atresia: Current concepts and research directions—Summary of symposium. *Hepatology* 6:1682-1692, 1996
- Ohi R, Hanamatsu M, Mochizuki I, et al: Progress in the treatment of biliary atresia. *World J Surg* 9:285-293, 1985
- Yamataka A, Kuwatsuru R, Shima H, et al: Initial experience with non-breath-hold magnetic resonance cholangiopancreatography: A new noninvasive technique for the diagnosis of choledochal cyst in children. *J Pediatr Surg* 32:1560-1562, 1997
- Han SJ, Kim MJ, Chung KS, et al: Usefulness and limitation of magnetic resonance cholangiopancreatography as diagnostic tool for biliary disorder in children. Presented at the 15th Congress of Asian Association of Pediatric Surgeons, Suzhou, China, Sept 27-Oct 1, 1998
- Guibaud L, Lachaud A, Touraine R, et al: MR cholangiography in neonates and infants: Feasibility and preliminary application. *Am J Roentgenol* 170:27-31, 1998
- Kim MJ, Park YN, Han SJ, et al: Biliary atresia in neonates and infants: Triangular area of high signal intensity in the porta hepatis at T2-weighted MR cholangiography with US and Histopathologic correlation. *Radiology* 215:395-401, 2000
- Kasai M, Sawagucji S, Akiyama T, et al: A proposal of new classification of biliary atresia. *J Jpn Soc Pediatr Surg* 12:327-331, 1976
- Steward BA, Hall RJ, Karrer FM, et al: Long-term survival after Kasai's operation for biliary atresia. *Pediatr Surg Int* 5:87-90, 1990
- Abramson SJ, Treves S, Teele RL: The infant with possible biliary atresia: Evaluation by ultrasound and nuclear medicine. *Pediatr Radiol* 12:1-5, 1982
- Williamson SL, Seibert JJ, Butler HL, et al: Apparent gut excretion of Tc-99m-DISIDA in a case of extrahepatic biliary atresia. *Pediatr Radiol* 16:245-257, 1986
- Lai MW, Chang MH, Hsu SC, et al: Differential diagnosis of extrahepatic biliary atresia from neonatal hepatitis: A prospective study. *J Pediatr Gastroenterol Nutr* 18:121-127, 1994
- Brough AJ, Bernstein J: Conjugated hyperbilirubinemia in early infancy. A reassessment of liver biopsy. *Hum Pathol* 5:507-516, 1974
- Ohnuma N, Takahashi H, Tanabe M, et al: Endoscopic retrograde cholangiopancreatography (ERCP) in biliary tract diseases of infants less than one year old. *Tohoku J Exp Med* 181:67-74, 1997
- Ohnuma N, Takahashi T, Tanabe M, et al: The role of ERCP in biliary atresia. *Gastrointest Endosc* 45:365-370, 1997
- Wilkinson ML, Mieli-Vergani G, Ball C, et al: Endoscopic retrograde cholangiopancreatography in infantile cholestasis. *Arch Dis Child* 66:121-123, 1991
- Carty H: Percutaneous transhepatic fine needle cholangiography in jaundiced infants. *Ann Radiol* 21:149-154, 1977
- Franken EA, Smith WL, Smith JA, et al: Percutaneous cholangiography in infants. *AJR* 130:1057-1058, 1978

18. Hay SA, Soliman HE, Sherif HM, et al: Neonatal jaundice: The role of laparoscopy. *J Pediatr Surg* 35:1706-1709, 2000
19. Peng SS, Li YW, Chang MH, et al: Magnetic resonance cholangiography for evaluation of cholestatic jaundice in neonates and infants. *J Formos Med Assoc* 97:698-703, 1998
20. Guibaud L, Lachaud A, Touraine R, et al: MR cholangiography in neonates and infants: Feasibility and preliminary applications. *AJR* 170:27-31, 1998
21. Miyazaki T, Yamashita Y, Tang Y, et al: Single-shot MR cholangiopancreatography of neonates, infants, and young children. *AJR* 170:33-37, 1998
22. Jaw TS, Kuo YT, Liu GC, et al: MR cholangiography in the evaluation of neonatal cholestasis. *Radiology* 212:249-256, 1999
23. Shirahase I, Ooshima A, Tanaka K, et al: The slow progression of hepatic fibrosis in intrahepatic cholestasis as compared with extrahepatic biliary atresia. *Eur J Pediatr Surg* 5:77-81, 1995
24. Park WH, Choi SO, Lee HJ, et al: A new diagnostic approach to biliary atresia with emphasis on the ultrasonographic triangular cord sign: Comparison of ultrasonography, hepatobiliary scintigraphy, and liver needle biopsy in the evaluation of infantile cholestasis. *J Pediatr Surg* 32:1555-1559, 1997