



## GUIDELINES

**Viewpoints**, pertaining to issues of general interest, are welcome, even if they are not related to items previously published. Viewpoints may present unique techniques, brief technology updates, technical notes, and so on. Viewpoints will be published on

a space-available basis because they are typically less time-sensitive than Letters and other types of articles. Please note the following criteria:

- Text—maximum of 500 words (not including references)
- References—maximum of five
- Authors—no more than five
- Figures/Tables—no more than two figures and/or one table

Authors will be listed in the order in which they appear in the submission. Viewpoints should be submitted electronically via PRS' *enkwel*, at [www.editorialmanager.com/prs/](http://www.editorialmanager.com/prs/). We strongly encourage authors to submit figures in color.

We reserve the right to edit Viewpoints to meet requirements of space and format. Any financial interests relevant to the content must be disclosed. Submission of a Viewpoint constitutes permission for the American Society of Plastic Surgeons and its licensees and assignees to publish it in the *Journal* and in any other form or medium.

The views, opinions, and conclusions expressed in the Viewpoints represent the personal opinions of the individual writers and not those of the publisher, the Editorial Board, or the sponsors of the *Journal*. Any stated views, opinions, and conclusions do not reflect the policy of any of the sponsoring organizations or of the institutions with which the writer is affiliated, and the publisher, the Editorial Board, and the sponsoring organizations assume no responsibility for the content of such correspondence.

## Viewpoints

### 990 Form: A Taxing Burden for Cleft Organizations

Sir:

Opponents of medical missions justify their stance by frequently citing the cost savings derived from allowing local surgeons to perform the operations. In Cambodia, it costs local surgeons U.S. \$80 per cleft lip reconstruction, whereas an international medical mission may face expenses of U.S. \$1000 for the same procedure.<sup>1</sup> This reduces the argument to an economic one, where evaluations of cleft organizations are based heavily on 990 tax forms, focusing specifically on treatment costs and number of children treated. Using Operation Smile as a model, we demonstrate that such a myopic view fails to consider the feasibility of local surgeons performing cleft repair, the quality of the surgery maintained, and the intangible, unquantifiable stream of benefits of mission trips, all of which remain critical in evaluating cleft organizations.

■ Copyright ©2009 by the American Society of Plastic Surgeons

The reality, however, is that all forms of support of children with clefts are important. In most developing countries, local surgeons receive little or no reimbursement for their efforts to routinely repair these cleft deformities, and the dearth of specialists such as pediatric anesthesiologists and intensivists prevents the assembly of multidisciplinary teams necessary for mitigating the risks in cleft repair.<sup>2,3</sup> Therefore, many patients in these nations do not receive treatment from local providers and continue to experience clinical complications and the social stigma associated with these untreated facial deformities. Operation Smile's medical missions fill this void by providing surgical care for local populations while facilitating the training of local and international plastic surgeons and specialists through programs such as its annual Physicians' Training Program.<sup>4</sup>

As nonprofit rating services tend to rely heavily on the treatment expense per child for evaluating cleft charities, the pressure for these organizations to demonstrate a low treatment expense or a high annual number of children treated on their 990 forms continues to mount. Simple comparisons of 990 forms do not account for the organization that partially funds a mission (perhaps only the plane ticket for a surgeon on the trip) and still counts all the children treated on that surgeon's mission in its yearly total, inevitably lowering its treatment expense per child. Furthermore, the 990 form provides no information regarding how an organization handles postoperative complications, assuming a system has been implemented to notify the organization about these complications, nor do the forms include information regarding the credentials of those treating the children.

1. Operation Smile's funds cover all aspects of the mission, from hotel rooms to speech therapists for children undergoing palate repair.
2. Operation Smile's comprehensive care centers monitor and treat postoperative complications year round.
3. Operation Smile's internal review ensures that all mission members meet standard accreditations.

Appraising intangible benefits that Operation Smile produces by advancing the understanding and management of congenital facial deformities through university partnerships or by inspiring individuals to pursue careers in international health care by permitting medical students and residents on missions is inherently difficult to quantify and list on a 990 form.

We recommend that those critics harping on the costs of mission trips consider the ethical dilemma of saving dollars at the expense of quality of care that occurs when paying local surgeons (who may lack the appropriate training) or other specialists necessary for optimal cleft repair. Analyzing other rubrics, including qualitative metrics not on a 990 form, will be a starting

point for fathoming the value that cleft organizations such as Operation Smile engender for society and for evaluating cleft organizations more accurately.<sup>5</sup>  
DOI: 10.1097/PRS.0b013e3181bcf7a7

Anup Patel, B.S.

John A. Persing, M.D.

Section of Plastic and Reconstructive Surgery  
Yale University School of Medicine  
New Haven, Conn.

Correspondence to Dr. Persing  
Section of Plastic and Reconstructive Surgery  
Yale University School of Medicine  
P.O. Box 8041  
New Haven, Conn. 06520-8062  
john.persing@yale.edu

### DISCLOSURE

Neither of the authors has any commercial associations or financial disclosures that would create a conflict of interest with information presented in this article.

### REFERENCES

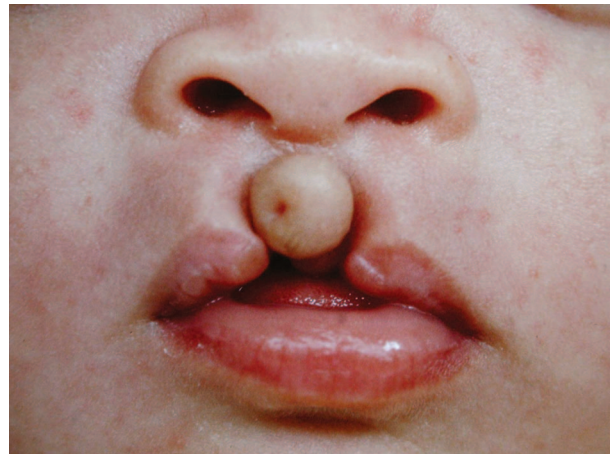1. Dupuis CC. Humanitarian missions in the third world: A polite dissent. *Plast Reconstr Surg.* 2004;113:433–435.
2. Mulliken JB. The changing faces of children with cleft lip and palate. *N Engl J Med.* 2004;351:745–747.
3. Bermudez RLE. Operation Smile: Plastic surgery with few resources. *Lancet* 2000;356:S45.
4. Poe D. Operation Smile International: Missions of mercy. *Plast Surg Nurs.* 1994;14:225–230.
5. Collins J. *Good to Great and the Social Sectors: Why Business Thinking Is Not the Answer.* Boulder, Colo: Jim Collins; 2005.

## Microform or Incomplete Median Cleft Lip: Strategy and Management

Sir:

**M**edian cleft of the upper lip is a congenital midline vertical cleft because of the absence of the prolabium. Long-term data and a treatment algorithm for the minor form of median cleft deformity and its associated problem (e.g., frenula anomalies and upper incisor diastema) are lacking.

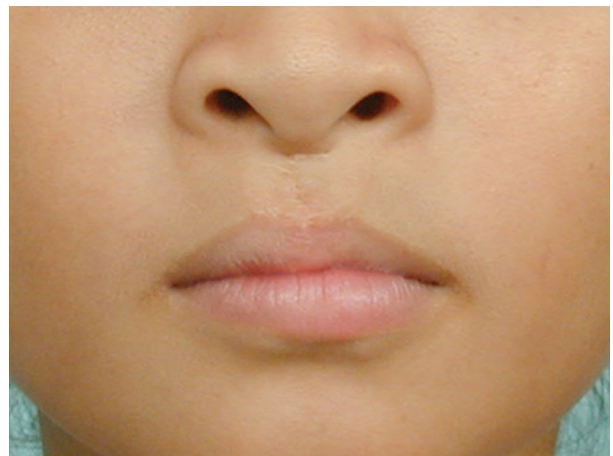This retrospective review includes five patients between 1982 to 1994, two male and three female patients. The follow-up ranged from 10 to 20 years. The patients exhibited microform median cleft of the upper lip and survived like other normal infants. The straight-line lip repair was performed at 3 months of age (Fig. 1) and followed by orthodontic treatment. The skin lining was excised and the mucosa, orbicularis oris muscle, and skin were repaired without Z-plasty or other lengthening techniques. Alveolar bone grafting was also performed at the age of 5 years, before eruption of the permanent maxillary incisors.<sup>1</sup> The results were evaluated by using the classification published by Abyholm et al.<sup>2</sup> and evaluated by occlusal radiographs 1 week, 6 months, and 1 year after surgery.



**Fig. 1.** One midline notch on the upper lip and extending half-way up the philtrum. A median dysgenesis remnant was localized in the central part of the philtrum.

An aesthetic and symmetrical philtrum column and upper lip were achieved. The length of the philtrum column was adequate (Fig. 2). All patients achieved type I results of alveolar bone grafting, and the dental radiographs showed new bone reaching alveolar ridges. Long-term dental occlusion proved stable results of diastema correction.

Pathologic findings of the remnant in the first case demonstrated cutaneous tissue with a partial cartilaginous component that was different from the pure cutaneous component in other articles. In this series, the straight-line technique was chosen instead of the forked flap procedure described by Millard to correct the upper lip notch at 3 months of age.<sup>3</sup> The midline ridge was excised, narrowed, and lengthened by advancement of the forked flap in his series. The straight-line mark along the bilateral philtrum column margin was designed. Simple excision helps narrow the col-



**Fig. 2.** Good symmetry of vermilion and Cupid's bow, minimized scar formation, and adequate length of the upper lip were achieved.

umn, maintain the concavity, and avoid altering the Cupid's bow and tubercle. The adequate length and nondisfigured philtrum and symmetric upper lip indicate that it was not necessary to use specific techniques to camouflage the upper lip scar.

A median cleft associated with alveolus cleft and diastema has been described.<sup>4</sup> Diastema caused by midline bony clefts tends to relapse earlier and was resistant to conventional treatment.<sup>5</sup> The relationship between notching on the upper lip and relapse of maxillary diastema was also reported. A V-shaped bony cleft between two central incisors typically occurs in these patients. The bony cleft interrupts the formation of transeptal fibers and fails to proliferate across the midline cleft. In brief, restoration of bony support should precede the orthodontic correction in incisor diastema.

Early secondary bone grafting was performed between 4 and 7 years of age. We recommend bone grafting at the age of 5 years, before permanent incisor eruption. Successful bone grafting provides better support when new teeth erupt and helps maintain subsequent orthodontic results. In our series, diastema larger than 4 mm may be aesthetically and functionally restored by early bone grafting.

DOI: 10.1097/PRS.0b013e3181bcf51e

**Erh-Kang Chou, M.D.**

Department of Plastic Surgery  
China Medical University Hospital  
Taichung, and  
School of Medicine  
China Medical University  
Taichung, Taiwan

**Ellen Wen-Ching Ko, D.D.S., M.S.**

Department of Dentistry

**Philip Kuo-Ting Chen, M.D.**

Department of Plastic Surgery  
Chang Gung Memorial Hospital  
Chang Gung University College of Medicine  
Taoyuan, Taiwan

**Jack Chung-Kai Yu, M.D., D.M.D.**

Section of Plastic and Reconstructive Surgery  
Medical College of Georgia  
Augusta, Ga.

**Sophia Chia-Ning Chang, M.D., Ph.D.**

Department of Plastic Surgery  
China Medical University Hospital  
Taichung, and  
School of Medicine  
China Medical University  
Taichung, Taiwan

Correspondence to Dr. Chang  
Department of Plastic Surgery  
China Medical University Hospital  
School of Medicine  
China Medical University  
2 Yuh Der Road  
Taichung City 404, Taiwan  
scnchang@mail.cmu.edu.tw

## REFERENCES

1. Chen KT, Huang CS, Noordhoff SM. Alveolar bone grafting in unilateral complete cleft lip and palate patients. *Changcheng Yi Xue Za Zhi* 1994;17:226-234.
2. Abyholm FE, Bergland O, Semb G. Secondary bone grafting of alveolar clefts: A surgical/orthodontic treatment enabling a non-prosthetic rehabilitation in cleft lip and palate patients. *Scand J Plast Reconstr Surg*. 1981;15:127-140.
3. Millard DR Jr, Williams S. Median lip clefts of the upper lip. *Plast Reconstr Surg*. 1968;42:4-14.
4. Bishara SE, Wilson LF, Perez PT, O'Connor JE, Peniche RH. Dentofacial findings in a child with unrepaired median cleft of the lip at 4 years of age. *Am J Orthod*. 1985;88:157-162.
5. Stublely R. The influence of transeptal fibers on incisor position and diastema formation. *Am J Orthod*. 1976;70:645-662.

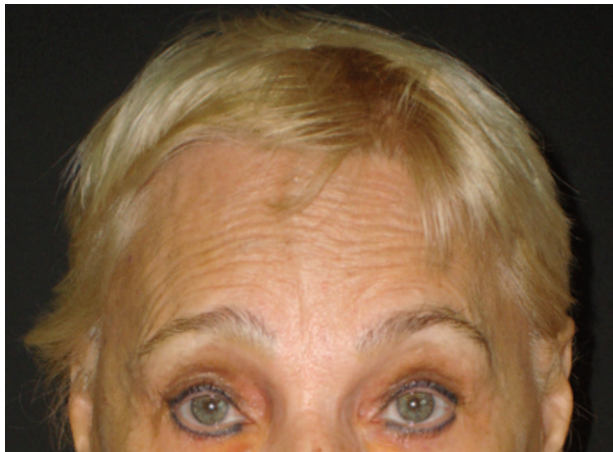## Minimally Invasive Treatment of Dynamic Horizontal Forehead Lines

*Sir:*

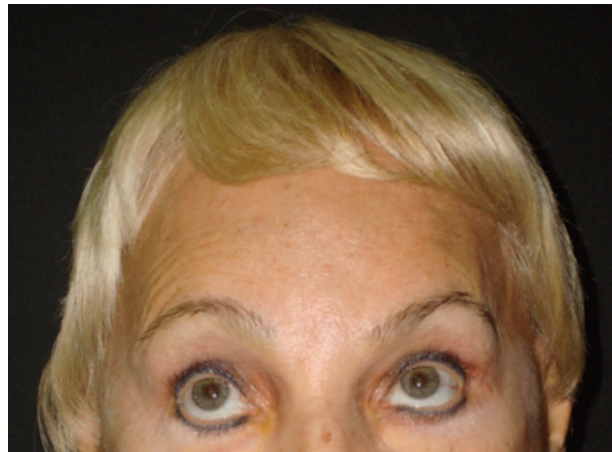Facial mimetic muscle action reveals itself over time by means of the development of forehead rhytides. Plastic surgeons have at their disposal several effective medical and surgical interventions to address these changes.<sup>1,2</sup> Each technique has merits and suitable applications. Since the introduction of endoscopic surgical techniques, an evolution from the standard coronal forehead lift to a minimally invasive one has occurred. The treatment of facial lines though, with botulinum toxin type A, has truly changed the concepts held by physicians regarding facial rejuvenation, mainly on the upper aspect of the face. It is one of the most common cosmetic procedures currently performed by physicians.<sup>2</sup> We report a new surgical approach for the treatment of dynamic horizontal forehead lines.

A 57-year-old woman with dynamic forehead lines is shown in Figure 1. The expected path of the supraorbital and supratrochlear neurovascular bundles through preoperative marking of their meridians is respected. After infiltrating the forehead with lidocaine 0.5%, bupivacaine 0.125%, and epinephrine 1:240,000, subperiosteal dissection is performed without the use of an endoscope by means of a unique 1-cm median intracapillary incision 0.5 cm behind the hairline. The dissection is safe until 1.5 cm above the superior orbital rim and laterally until an imaginary line that crosses the lateral border of the pupil (Fig. 2). On completion of dissection, a knife with a no. 15 blade is inserted and multiple vertical myotomies are performed. Depending on the extent of the horizontal forehead lines, usually five to seven vertical and horizontal myotomies are performed. Postoperative Micropore taping of the forehead for 48 hours is recommended. No postoperative complications were noted apart from swelling, which lasts 5 to 7 days. The patient expressed her satisfac-

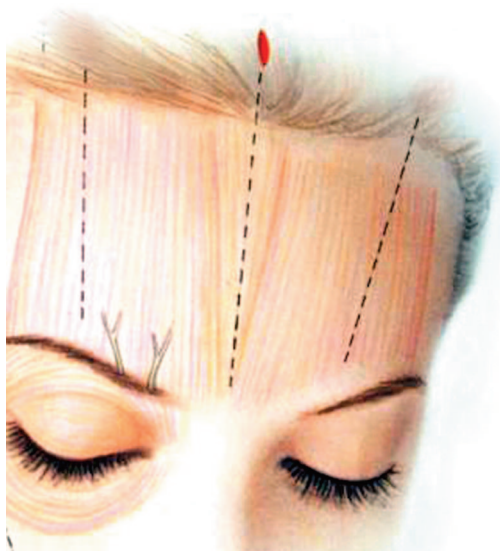




**Fig. 1.** Preoperative view of a 57-year-old woman with dynamic forehead lines.



**Fig. 3.** Postoperative view 1 year after treatment.



**Fig. 2.** Schematic representation of the incision and the limits of the dissection.

tion regarding the final result. The postoperative view 1 year after treatment is shown in Figure 3.

The frontal myotomies performed under direct visualization during a coronal lift have been proven to be an effective treatment for the dynamic horizontal forehead lines.<sup>3</sup> The endoscopic forehead treatment avoids many of the undesirable results of the coronal approach yet remains very efficacious for the treatment of forehead lines. However, it is expensive and has a significant learning curve. The use of injectable agents, specifically botulinum toxin type A, has risen dramatically over recent years for the treatment of forehead transverse lines, because of the increased demand for minimally invasive techniques. However, the cost of botulinum toxin type A remains one of the primary concerns for repeated application, and patients seek a more definitive treatment.<sup>4,5</sup>

This nonendoscopic, low-cost, easy-to-perform procedure has not been previously described and provides another option that can be used for the treatment of horizontal forehead lines. Further cases need to be performed to better define long-term results.

DOI: 10.1097/PRS.0b013e3181bcf5a7

**Enzo Rivera Citarella, M.D.**

**Aris Sterodimas, M.D., M.Sc.**

**Alexandra Condé-Green, M.D.**

Department of Plastic Surgery  
Pontifical Catholic University of Rio de Janeiro and the  
Carlos Chagas Post-Graduate Medical Institute  
Rio de Janeiro, Brazil

Correspondence to Dr. Sterodimas  
Department of Plastic Surgery  
Pontifical Catholic University of Rio de Janeiro and the  
Carlos Chagas Post-Graduate Medical Institute  
Av. Beira Mar 406  
Rio de Janeiro, Brazil

## REFERENCES

1. Rohrich RJ. Advances in facial rejuvenation: Botulinum toxin A, Hyaluronic acid dermal fillers, and combination therapies—Consensus recommendations. Editor's Foreword. *Plast Reconstr Surg.* 2008;121 (5 Suppl.):1S–2S.
2. Presti P, Yalamanchili H, Honrado CP. Rejuvenation of the aging upper third of the face. *Facial Plast Surg.* 2006;22: 91–96.
3. Carruthers JD, Glogau RG, Blitzer A. Facial Aesthetics Consensus Group Faculty. Advances in facial rejuvenation: Botulinum toxin type A, hyaluronic acid dermal fillers, and combination therapies—Consensus recommendations. *Plast Reconstr Surg.* 2008;121 (5 Suppl.):5S–30S; quiz 31S–36S.
4. Flowers RS, Ceydeli A. The open coronal approach to forehead rejuvenation. *Clin Plast Surg.* 2008;35:331–351; discussion 329.
5. Lee H, Saladi RN, Fox JL. Cohort study on patient response to botulinum toxin cosmetic therapy. *J Cosmet Dermatol.* 2008; 7:39–42.

## Timing Ear Reconstruction by Biomechanical Properties of the Rib Cartilage: Is Childhood the Best Operative Time?

Sir:

**A**uricular reconstruction is one of the most troublesome and complicated operations. Presently, autogenous costal cartilage is the first choice for reconstructing the auricular framework; therefore, it is important to understand the biomechanical properties of rib cartilage for sustaining the outline form to achieve a satisfactory postoperative effect.

Ninety human costal cartilages of the seventh middle section were obtained after ear reconstruction from tissues left over after surgery. The tensile strength test, the stress and strain test, and the creep and stress relaxation test were performed in vitro using an Instron materials testing machine (type 4302; Instron Ltd, High Wycombe, United Kingdom). The specimens were divided into six different groups as follows: children (5 to 10 years old), marked A in girls and A1 in boys; adolescents (11 to 17 years old), marked B in girls and B1 in boys; and adults (18 to 29 years old), marked C in women and C1 in men. Each group had 15 male and female subjects.

In auricular reconstruction, the curved auricular frame is a multilayer, three-dimensional stereo structure; it needs mechanical strength to sustain its stability. Its satisfactory mechanical properties help the cartilage frame to resist the absorption and deformation, thereby ensuring the further effect of surgery. Two aspects are considered—psychology and physiology—when making the choice regarding the timing of auricular reconstruction surgery. From the standpoint of psychology, the sooner the better, to avoid unhealthy psychological effects on the child patient. Zhuang et al.,<sup>1</sup> Brent,<sup>2</sup> and Fukuda<sup>3</sup> believe the operation should be performed before the patient is 6 or 7 years of age. From the standpoint of physiology, the timing depends on whether the size of the auricle reaches or approximates that of the adult size and whether the size of the costal cartilage satisfies the need for a curved frame. Tanino and Miyasaka<sup>4</sup> pointed out that a curved auricular frame needs a lot cartilage tissue, so 8 to 10 years is the ideal age. At the same time, Qi keming et al.<sup>5</sup> had conducted a study that included 1057 different-age, normal Chinese people through measuring their auricular size to demonstrate that in children of school age and younger, the auricle is 0.9 cm smaller than in adults. Therefore, they pointed out that the operation should be performed after 13 years of age.

The results of this study show that the tensile strength in the group consisting of children was significantly higher than that in the adolescent and adult groups in both male and female groups. This could be because of the different collagen structure that exists in children. The stress and strain test and the creep and stress relaxation test show that the group of children had cartilage that was the most flexible and the most resistant to deformation. This

phenomenon could be explained by cartilage calcification and ossification, which increased the stiffness in the adult groups. The calcification and the stiffness of cartilage increase with age; thus, cartilage is not suitable for use as a frame material for auricular reconstruction after the age of 29 years.

In summary, integrating psychological, physiologic, and biomechanical properties, our results indicate that auricular reconstruction surgery using costal cartilage should be performed during childhood to take advantage of the best biomechanical properties.

DOI: 10.1097/PRS.0b013e3181bcf791

**Qing-hua Yang, M.D.**

**Yu-peng Song, M.D.**

**Hai-yue Jiang, M.D.**

**Le-ren He, M.D.**

**Shu-jie Wang, M.D.**

Plastic Surgery Hospital  
Peking Union Medical College  
Chinese Academy of Medical Sciences  
Beijing, China

Correspondence to Dr. Yang  
Plastic Surgery Hospital  
Peking Union Medical College  
Chinese Academy of Medical Sciences  
Beijing 100144, China  
yangpsh@126.com

### ACKNOWLEDGMENTS

*This work was supported by the Plastic Surgery Hospital, Peking Union Medical College, Chinese Academy of Medical Sciences. The authors thank the patients and their families for their kind cooperation with this research.*

### REFERENCES

1. Zhuang HX, Jiang HY, Pan B, et al. Ear reconstruction using soft tissue expander in the treatment of congenital microtia (in Chinese). *Zhonghua Zheng Xing Wai Ke Za Zhi* 2006;22:286–289.
2. Brent B. Microtia repair with rib cartilage grafts: A review of personal experience with 1000 cases. *Clin Plast Surg*. 2002;29:257–272.
3. Fukuda O. Long-term evaluation of modified Tanzer ear reconstruction. *Clin Plast Surg*. 1990;17:241–249.
4. Tanino R, Miyasaka M. Reconstruction of microtia using tissue expander. *Clin Plast Surg*. 1990;17:339–353.
5. Qi keming, Bo jie, Xiong bin, et al. The research about auricular development in Chinese and the choice of timing for auricular reconstruction (in Chinese). *Zhonghua Zheng Xing Wai Ke Za Zhi* 1990;6:136–137.

### A Novel Application of Vacuum-Assisted Closure in Auricular Reconstruction

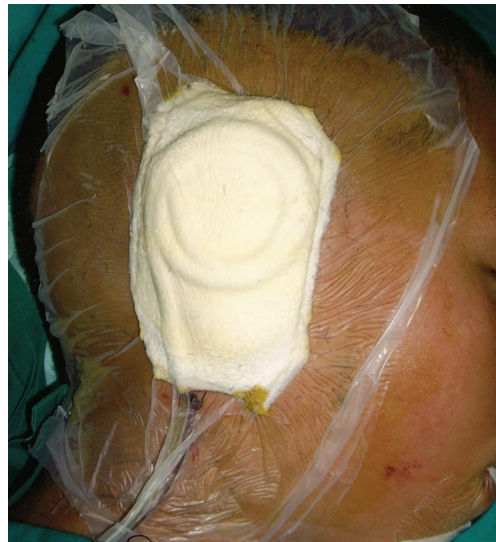Sir:

**A**uricular reconstruction is a challenge for the reconstructive surgeon. In the majority of cases, autogenous costal cartilage grafts are used as scaffolding.



folds for the overlying soft-tissue envelope. Critical to all currently used techniques is adequate protection of the graft from infection and edema during the early postoperative period. Brent described a suction drainage system with two thin catheters within the tissue envelope to facilitate redraping of the skin to the underlying cartilage framework.<sup>1</sup> The drains were attached to vacuum blood sample tubes. However, some disadvantages are evident. First, the negative pressure inside the vacuum tubes varies between tubes and is impossible to quantify. Tubes must be changed every 2 to 3 hours over the initial 3 to 4 postoperative days (i.e., 24 to 48 times in total). This leads to repeated windows for loss of vacuum pressure, each causing shear forces across the fragile graft. Changing tubes adds an unnecessary workload for already busy nursing staff. We propose a novel application of the vacuum-assisted closure protocol. This system develops the cost-effective technique designed by Brent, but uses a more reliable vacuum apparatus that requires less monitoring.

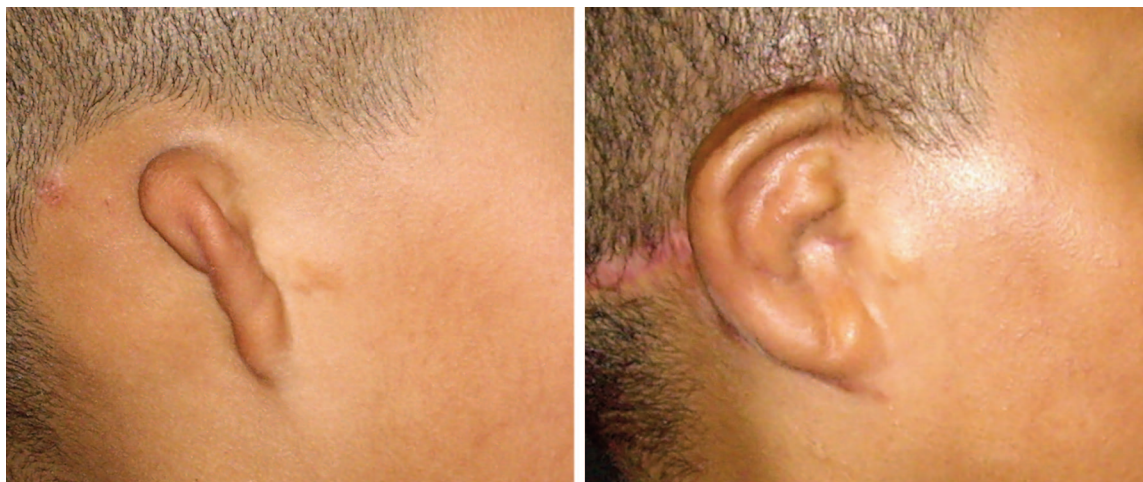In auricular reconstruction, we follow the two-stage procedure described by Nagata<sup>2</sup> and Firmin<sup>3</sup> (Fig. 1). Posttraumatic cases are treated with a one-stage procedure. Two 3.2-mm-diameter Redon drainage tubes are inserted, with the first placed within the tissue envelope next to the helix of the cartilage graft, exiting the skin approximately 2 to 5 cm inferior to the lobule. An open-cell sponge is placed over the flap. The second tube rests within a pocket created in the open-cell sponge, and both tubes are connected by means of a Y-junction. The system is enclosed in an occlusive dressing (OpSite; Smith & Nephew, Columbus, S.C.) (Fig. 2). The vacuum complex is connected in the operating room to a 3.2-mm Porto-Vac drain (Stryker Instruments, Portage, Mich.) and then clamped and transferred to wall suction in the ward. Negative pressure is kept at the minimum level required to eliminate dead space inside the soft-tissue envelope (120 to 150 mmHg). The



**Fig. 2.** Intraoperative view showing our adaptation of the vacuum-assisted closure technique.

vacuum-assisted closure system is left undisturbed for 4 to 5 days on the ward before being changed to a nonvacuum dressing for an additional week.

The proposed adaptation of the vacuum-assisted closure technique has several advantages. The contour of the reconstructed auricle is visualized in the theater and maintained over the following days, facilitating coaptation. This eliminates the issue of irregular contour for flap-scaffold apposition. Second, edema is reduced, improving vascular perfusion and lymphatic flow and reducing potential bacterial load.<sup>4</sup> These factors act in concert to improve take of the reconstructed auricle complex. Intervention required from ward staff is reduced, as vacuum systems are untouched for 4 to 5 days. As in all systems, disadvantages do exist. The primary disadvantage is increased length of ward stay, as patients must stay in



**Fig. 1.** A patient with unilateral microtia before surgery (*left*) and after stage 2 (*right*).

proximity to the central vacuum system. In a private hospital setting, a commercially available mobile vacuum-assisted closure system (V.A.C.; KCI, Inc., San Antonio, Texas) has been tested successfully in similar patients, with the advantage of enhanced patient mobility with monitoring on an outpatient basis. Our suggested modification demonstrates a novel application of the vacuum-assisted closure technique and has been proven safe and simple to apply and provides excellent reconstructive outcomes.

DOI: 10.1097/PRS.0b013e3181bcf27c

**Frank R. Graewe, M.D.**

Division of Plastic and Reconstructive Surgery  
Stellenbosch University  
Cape Town, South Africa

**Richard J. Ross, B.Sc.(Hons.)**

School of Medicine  
Faculty of Health Sciences  
Flinders University  
South Australia, Australia

**Tim Perks, M.D.**

**Chris van der Walt, M.D.**

**Alexander E. Zuehlke, M.D.**

Division of Plastic and Reconstructive Surgery  
Stellenbosch University  
Cape Town, South Africa

Correspondence to Dr. Graewe  
Division of Plastic and Reconstructive Surgery  
Faculty of Health Sciences  
University of Stellenbosch  
Francie van Zyl Drive  
P.O. Box 19063  
Tygerberg, Western Cape 7505, South Africa  
graewe@sun.ac.za

## REFERENCES

1. Brent B. The correction of microtia with autogenous cartilage grafts: I. The classic deformity. *Plast Reconstr Surg.* 1980;66:1–12.
2. Nagata S. A new method of total reconstruction of the auricle for microtia. *Plast Reconstr Surg.* 1993;92:187–201.
3. Firmin F. Ear reconstruction in cases of typical microtia: Personal experience based on 352 microtic ear corrections. *Scand J Plast Reconstr Surg Hand Surg.* 1998;32:35–47.
4. Morykwas MJ, Simpson J, Pungler K, Argenta A, Kremers L, Argenta J. Vacuum-assisted closure: State of basic research and physiologic foundation. *Plast Reconstr Surg.* 2006;117 (Suppl): 121S–126S.

## Conchal Cartilage Sandwich Graft for Repairing Recalcitrant Acquired Split Earlobe Deformity

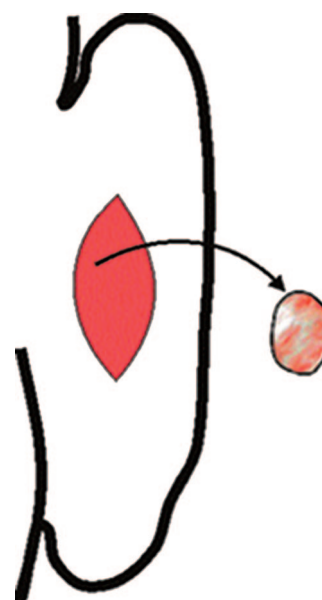
Sir:

A torn earlobe is by far the commonest cosmetic problem of the ear requiring surgery. Many techniques have been published for the repair of earlobe tears.<sup>1–3</sup> These techniques consist of simple suturing of the tear and use of flaps for preservation of the ear hole, in addition to description of many different types of

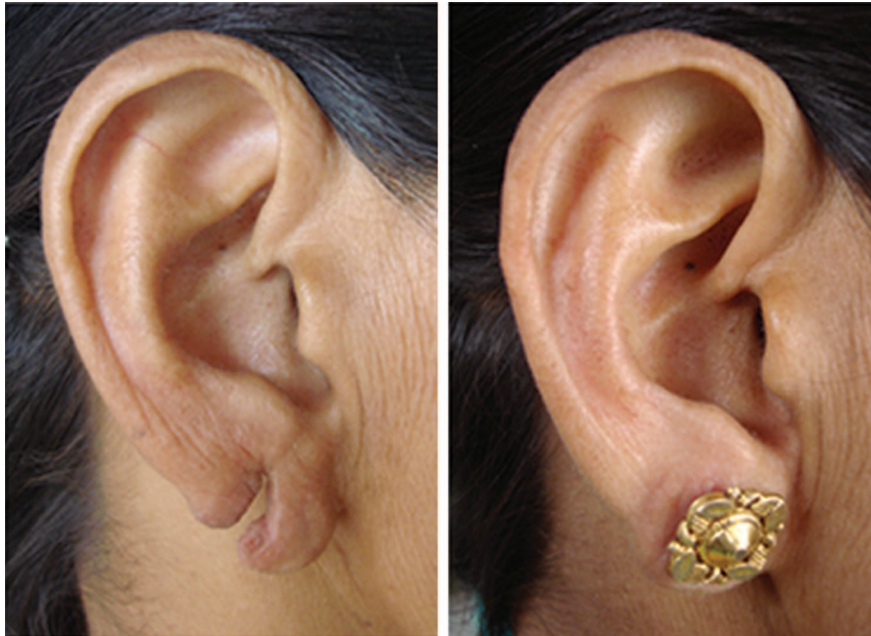flaps to provide strength to the earlobe below the repaired ear hole. All these surgical methods inadvertently tend to add to further scarring and weakening of the earlobe tissues, thus predisposing the earlobe to recurrent tears.

The reason for recurrent splitting of the earlobe lies in the anatomy of the earlobe, which is unique with regard to the direction of the split<sup>4</sup> and also because of anatomical weakness of the earlobe. The earlobe consists of skin and subcutaneous tissue but no internal architectural support of either cartilage, muscle, or fascial tissue. The soft structure of the earlobe is thus not strong enough to withstand the continuous trauma associated with long-term earring use, with its attendant problems of superadded incidental trauma caused by inadvertent pulling of the earring or even surgical scarring, which is unwittingly exacerbated by repeated repairs of split earlobe. The direction of the split of the earlobe is also unique.

A new technique has been developed that strengthens the earlobe with locally available conchal cartilage (Fig. 1) and provides the necessary reinforcement of earlobe tissues, preventing further recurrence following surgery. This technique also allows simultaneous creation of a centrally located ear hole, thus eliminating the waiting period between ear hole repair and reperforation. This technique involves harvesting a disk of conchal cartilage and implanting this disk into the repaired earlobe. A new ear hole is then created at a central location on the repaired split earlobe across the center of this cartilage disk in the same sitting. The patients thus have the satisfaction of leaving the operating room with earrings on, completely eliminating any waiting period between repair and reperforation.



**Fig. 1.** Diagram showing the harvesting of the conchal cartilage disk measuring approximately 1.5 cm in diameter.



**Fig. 2.** Clinical photograph of the right ear of a 42-year-old woman with complete split earlobe before repair (*left*) and after repair using conchal cartilage graft (*right*).

This technique thus allows durable repair of the earlobe by strengthening the tissues using conchal cartilage graft. It reduces the chance of recurrence and also facilitates simultaneous recreation of a central ear hole in the same setting (Fig. 2).

DOI: 10.1097/PRS.0b013e3181bcf228

**Rajiv Agarwal, M.D.**

**Ramesh Chandra, F.R.C.S.**

Department of Plastic Surgery  
C.S.M. Medical University  
Lucknow, India

Correspondence to Dr. Agarwal  
A-15 Nirala Nagar  
Lucknow 226020, India  
drrajivagarwal@rediffmail.com

#### DISCLOSURE

*The authors have no financial or commercial interests in the current study with any company.*

#### REFERENCES

1. Pardue AM. Repair of torn earlobe with preservation of the perforation for an earring. *Plast Reconstr Surg.* 1973;51:472–473.
2. Hamilton R, LaRossa D. Method for repair of cleft earlobes. *Plast Reconstr Surg.* 1975;55:99–101.
3. Agarwal R. Repair of cleft earlobe using double opposing Z-plasty. *Plast Reconstr Surg.* 1998;102:1759–1760.
4. Agarwal R, Chandra R. The anatomy of the split ear lobe. *J Plast Reconstr Aesthet Surg.* 2008;61 (Suppl. 1): S114.

#### Monozygotic Twin Sister as a Template for Facial Trauma Reconstruction

*Sir:*

**T**raumatic deformity of the cartilaginous septum is related to later underdevelopment of the cartilaginous middle third of the nose and disturbed maxillary growth.<sup>1,2</sup> Many studies retrospectively relate traumatic events to skeletal class III relations. However, these do not provide clear relationships between the environment and genetics.

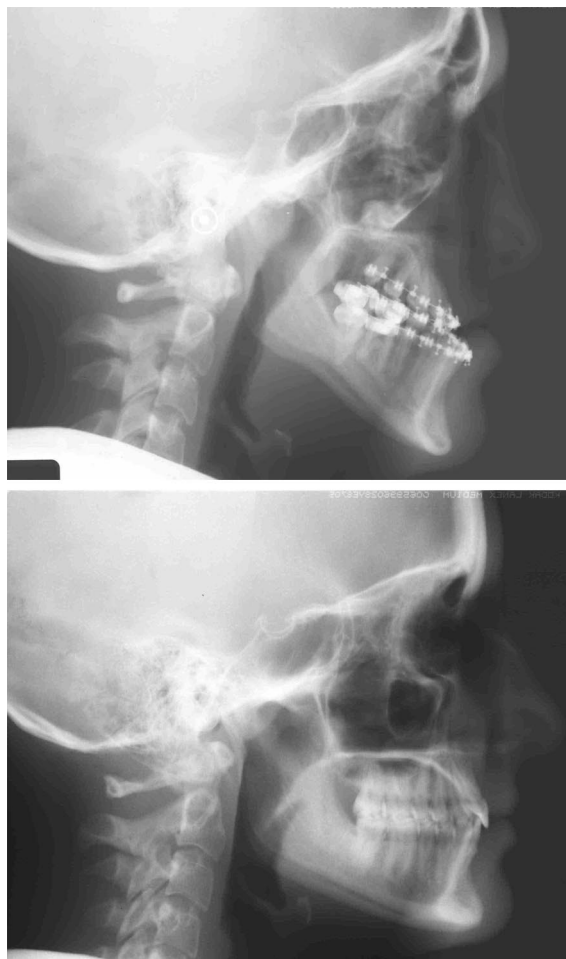
Twin studies have proven beneficial in separating genetic and environmental influences on facial growth and malocclusion. A review of the literature has revealed only one study of identical twins in which one sustained a traumatic injury to the midfacial region at a young age.<sup>3,4</sup>

The aim of this study was to compare longitudinally the growth of the face in a pair of identical twins after severe midfacial trauma (twin A) in early childhood and to present a method of facial reconstruction by the use of the normal twin sister's facial growth pattern as a template for the reconstruction.

One pair of female identical twins (twin A) was presented for consultation in relation to facial deformity because of midfacial trauma at age 2 that included Le Fort II and III fractures. Until age 19, the facial profile difference between the twins gradually became more pronounced and included, in twin A, severe retrusion, midfacial class III malocclusion, and a negative overbite relation of 9 mm with enlarged facial height.

Radiographic studies, including lateral and posteroanterior cephalometric and panoramic radiographs, were obtained at intervals during growth and development. The





**Fig. 1.** Preoperative lateral cephalograms obtained at the age of 19 years in twin A (*above*) and twin B (*below*).


preoperative cephalometric radiograph was taken at the age of 19 after a presurgical orthodontic preparation phase (Fig. 1, *above*) revealed a negative overjet of 12 mm. Cephalometric radiographs were at this time also obtained on the unaffected twin (Fig. 1, *below*). Cephalometric radiographs were analyzed and compared between twin A and twin B. Superimpositions of the cephalograms of both twins were performed for comparison and surgical planning (Fig. 2).

At the age of 20 years, twin A underwent surgical correction of the traumatic deformity according to the facial template phenotype of the unaffected twin sister. The orthognathic surgery procedure included a high Le Fort I osteotomy with maxillary advancement and impaction and with bilateral mandibular sagittal split osteotomy with setback associated genioplasty.

The present case demonstrates long-term follow-up of the influence of the facial trauma consisting of Le Fort II and III fractures. The comparison of the facial growth and development between twin A and twin B suggested that the cartilaginous septum and facial sutures plays an important role in the development of the nasomaxillary complex. Superimposition of the cephalometric radiographs before orthognathic surgery of the twin sisters (Fig. 2) revealed severely forward mandibular growth inhibition that resulted in significant posterior rotation of the nasal and maxillary bones and a vertical pattern of jaw growth. Because we compared two genetically identical twins, the disturbed nose and facial growth must be linked to the traumatized cartilaginous septum and facial sutures.

According to our observations in the patient presented here, it is suggested that trauma is most likely the cause of the developmental deformity of twin A. The unaffected twin sister (twin B) may serve as the genetic facial phenotype for the surgical orthognathic reconstruction intervention in twin A.

DOI: 10.1097/PRS.0b013e3181bcf535



**Fig. 2.** Superimposition of the preoperative cephalometric tracing of twin A with the tracing of twin B on the sella-nasion plain. (*Left*) The maxilla (twin A in black). (*Right*) Soft-tissue facial profile (twin A is represented by the dashed line).

**Dror Aizenbud, D.M.D., M.Sc.**

Orthodontic and Craniofacial Center  
Rambam Health Care Campus and Technion–Bruce  
Rappaport Faculty of Medicine  
Haifa, Israel

**Larry R. Morrill, D.D.S.**

**Stephen A. Schendel, M.D., D.D.S.**  
Craniofacial Anomalies Center  
Packard Children’s Hospital  
Stanford University School of Medicine  
Stanford, Calif.

Correspondence to Dr. Aizenbud  
Orthodontic and Craniofacial Center  
Rambam Health Care Campus  
P.O. Box 9602  
Haifa 31096, Israel  
aizenbud@ortho.co.il

**REFERENCES**

1. Meeuwis J, Verwoerd-Verhoef HL, Verwoerd CD. Normal and abnormal nasal growth after partial submucous resection of the cartilaginous septum. *Acta Otolaryngol.* 1993;113:379–382.
2. Verwoerd-Verhoef HL, Verwoerd CD. Surgery of the lateral nasal wall and ethmoid: Effects on sinonasal growth. An experimental study in rabbits. *Int J Pediatr Otorhinolaryngol.* 2003;67:263–269.
3. Grymer LF, Pallisgaard C, Melsen B. The nasal septum in relation to the development of the nasomaxillary complex: A study in identical twins. *Laryngoscope* 1991;101:863–868.
4. Grymer LF, Bosch C. The nasal septum and the development of the midface: A longitudinal study of a pair of monozygotic twins. *Rhinology* 1997;35:6–10.

**Use of Chimeric Subscapular Artery System Free Flaps for Soft-Tissue Reconstruction of the Oral Cavity and Oropharynx: Advantages and Donor-Site Morbidity**

Sir:

Reconstruction of extensive musculomucosal defects of the oral cavity and oropharynx is now based on the use of free flaps that have been demonstrated to be effective and versatile.<sup>1,2</sup>

One flap is usually harvested to reconstruct the entire defect. Even when a composite flap providing a

sufficient quantity of tissue is used, the spatial configuration of the flap is not always ideal. Chimeric subscapular artery system free flaps comprise spatially independent components, allowing a better anatomical result without plication of the flap, with only one vascular anastomosis. These flaps have been used in our center to improve the anatomical and functional results of reconstruction.

Between January 1, 2007, and January 31, 2007, a chimeric subscapular artery system free flap was performed in eight of the 60 free flaps performed in the unit (Table 1).

Five latissimus dorsi and serratus anterior free flaps; one latissimus dorsi and parascapular flap; one parascapular and serratus anterior flap; and one latissimus dorsi, serratus anterior, and parascapular flap were performed.

There were no flap failures or anastomotic revisions in this series. Four patients had intelligible speech and were able to talk on the telephone. One patient’s speech was difficult to understand. Two patients were able to eat a normal diet, two patients ate a soft diet, and one patient ate a semiliquid diet with half of the daily ration administered by gastrostomy. Three patients could not be evaluated.

No patient complained of chest pain or shoulder pain. The mean Disabilities of the Arm, Shoulder and Hand self-administered questionnaire score was 11.31.<sup>3</sup> No significant difference in the range of shoulder movement was observed between the operated side and the unoperated side (Table 2), and no case of scapula alata was observed.

Subscapular artery system flaps were used because of their numerous advantages. These chimeric flaps are composed of spatially independent flaps (latissimus dorsi, scapular, parascapular, and serratus anterior) with independent blood supplies, but with all sharing a common pedicle (subscapular artery). Microsurgery after flap transfer therefore requires only one vascular anastomosis.<sup>4</sup> These flaps are also composite (i.e., they can comprise several tissue components, such as skin, muscle, fascia, and bone).

It can be difficult to reconstruct the oropharynx, tongue, and the skin of the neck and cover the carotid

**Table 1. Clinical Characteristics of the Patients and Reconstruction**

Patient	Gender	Age (yr)	Follow-Up (mo)	Surgery	Flap	Status
1	Female	64	2	Total glossectomy	PS and S	ANED
2	Female	55	2	Total glossectomy	LD (MC) and S	Dead
3	Male	55	4	Anterior pelvic mandibulectomy	LD (MC) and S	Pulmonary metastasis
4	Female	48	10	Oropharyngectomy and hemimandibulectomy	PS and S and LD (M)	ANED
5	Male	56	9	Total glossectomy	LD (MC) and S	Pulmonary metastasis
6	Male	59	9	Total glossectomy	LD (MC) and S	AWED
7	Female	57	11	Total glossectomy	LD (MC) and S	ANED
8	Male	68	7	Extensive parotidectomy	LD (M) and PS	AWED

PS, parascapular flap; S, serratus anterior flap; LD, latissimus dorsi flap; MC, myocutaneous; M, muscular; ANED, alive with no evidence of disease; AWED, alive with evidence of disease.

**Table 2. Functional Results and DASH Score\***

Patient	Time after Surgery (mo)	Speech	Diet	DASH Score
1	2	Intelligible on the telephone	Soft	9.1
2	—	—	—	—
3	—	—	—	—
4	10	Intelligible on the telephone	Normal	20.6
5	9	—	—	5
6	9	Intelligible on the telephone	Soft	20.6
7	11	With difficulties	50/50 soft diet/gastrostomy	6.8
8	7	Normal	Normal	5.8

DASH, Disabilities of the Arm, Shoulder and Hand.

\*Patient 2 died, patient 3 could not attend the Institute, and patient 5 had total laryngectomy and esophageal closure.

artery with a single flap, because of the quantity of muscle and because of the three-dimensional configuration of the flap. Flap plication can impinge on the flap blood supply, but the reconstruction may be unsatisfactory without plication.

The normal mean Disabilities of the Arm, Shoulder and Hand score in the general population is 10.1.<sup>5</sup> It is therefore fairly remarkable that the Disabilities of the Arm, Shoulder and Hand score of patients undergoing a flap is equivalent to that of the general population. The same applies to the range of shoulder movement: shoulder movement was similar on the operated and unoperated sides.

In conclusion, the chimeric subscapular artery system free flap is a reliable solution for reconstruction of extensive soft-tissue defects of the oral cavity or oropharynx, allowing satisfactory three-dimensional conformation with a reliable flap blood supply without flap plication and with limited donor-site morbidity.

DOI: 10.1097/PRS.0b013e3181bcf7ba

**Angélique Girod, M.D.**

**Françoise Nadaud**

**Veronique Mosseri, M.D.**

**Thomas Jouffroy, M.D.**

**José Rodriguez, M.D.**

Head and Neck Oncologic Surgery Unit  
Institut Curie  
Paris, France

Correspondence to Dr. Girod  
Head and Neck Oncologic Surgery Unit  
Institut Curie  
26 rue d'ULM  
75005 Paris, France  
angelique.girod@curie.net

#### DISCLOSURE

The authors have no financial interests to disclose.

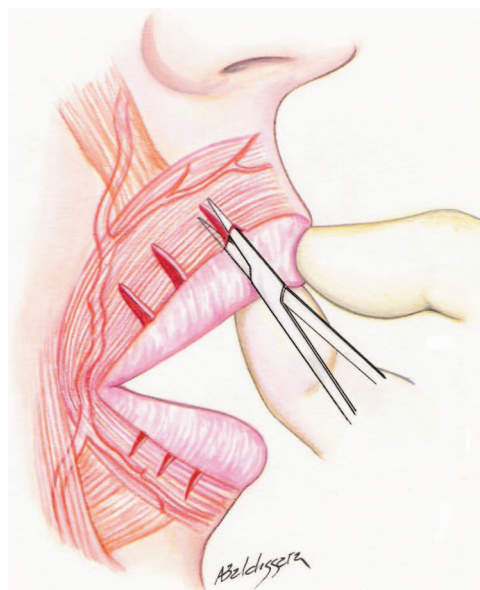
#### REFERENCES

- Haughey BH, Wilson E, Kluwe L, et al. Free flap reconstruction of the head and neck: Analysis of 241 cases. *Otolaryngol Head Neck Surg.* 2001;125:10–17.
- Suh JD, Sercarz JA, Abemayor E, et al. Analysis of outcome and complications in 400 cases of microvascular head and neck reconstruction. *Arch Otolaryngol Head Neck Surg.* 2004;130:962–966.
- Hudak PL, Amadio PC, Bombardier C. Development of an upper extremity outcome measure: The DASH (disabilities of the arm, shoulder and hand). The Upper Extremity Collaborative Group (UECG). *Am J Ind Med.* 1996;29:602–608.
- Hallock GG. Further clarification of the nomenclature for compound flaps. *Plast Reconstr Surg.* 2006;117:151e–160e.
- Hunsaker FG, Cioffi DA, Amadio PC. The American Academy of Orthopaedic Surgeons outcomes instruments: Normative values from the general population. *J Bone Joint Surg (Am.)* 2002;84:208–215.

#### Lip Rejuvenation Using Perioral Myotomies and Orbicularis Oculi Muscle as Autologous Filler

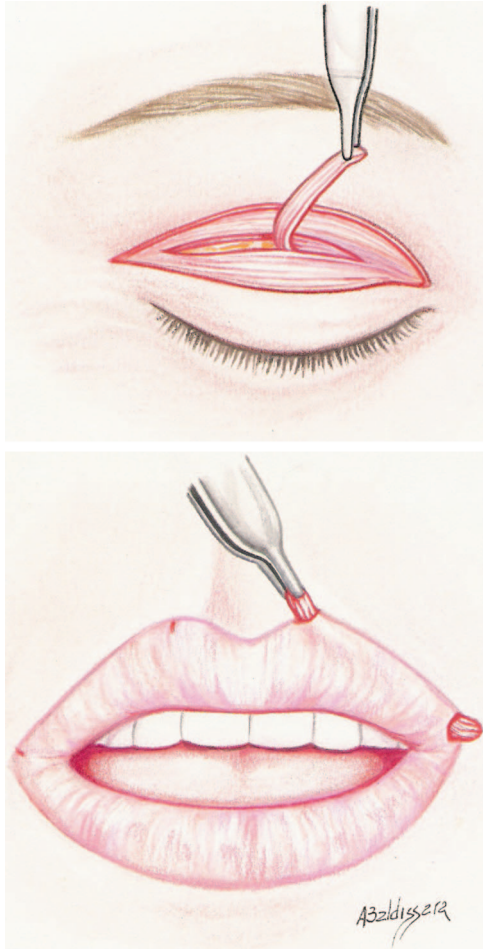
**Sir:**

Rejuvenation of the lips plays a key role in restoring a more youthful appearance. With aging, changes occur in the lips, such as vertical wrinkles, reduction in height of the vermilion border along with lengthening of the skin area of the lip, and “disappearance” of the Cupid’s bow.<sup>1</sup> Injectable fillers, botulinum toxin, autologous tissue grafts and fat grafting, lip lifts, lip advancements, and resurfacing procedures have been described in the literature. Temporary nonsurgical treatments and minimally invasive procedures are now the cutting edge lip rejuvenation treatments that attract the majority of the patients. However, with the increasing demand from patients comes an increasing challenge to surgeons to develop techniques that are suited



**Fig. 1.** Schematic representation of perioral myotomies.



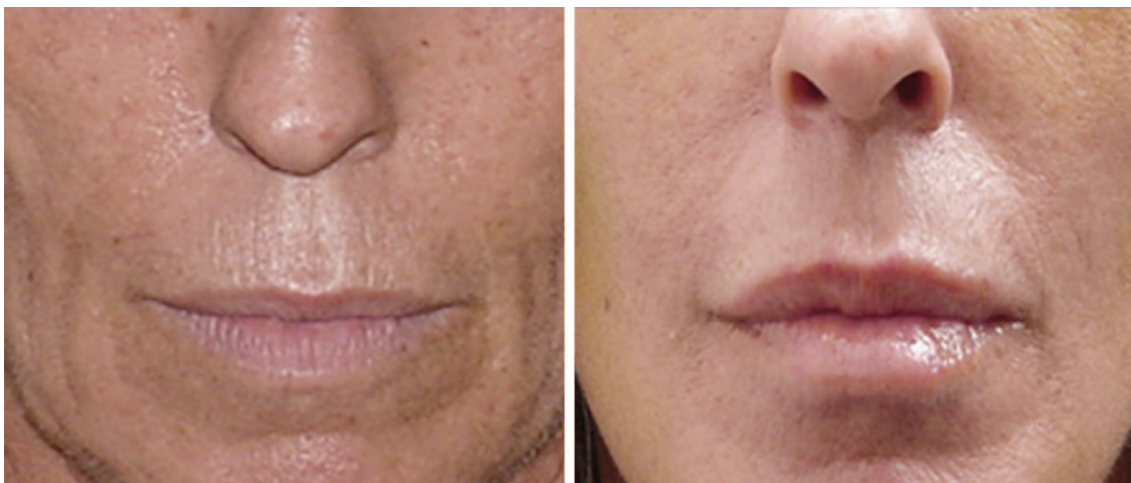

**Fig. 2.** Schematic representations of orbicularis oculi muscle strip excision during the superior blepharoplasty procedure and placement in the upper hemilip.

to the particular concerns, desires, and anatomy of each patient.<sup>2</sup> We report a new surgical method of lip rejuvenation.

After infiltration of both upper and lower lips with anesthetic solution consisting of lidocaine 0.5% and epinephrine 1:240,000, 2-mm horizontal incisions are made in the premarked areas at the level of the circumferential vermilion-skin border. Four incisions are made on each upper hemilip, the most medial one starting approximately 3 mm lateral to the Cupid's bow and the most lateral one ending approximately 3 mm from the angle of the mouth. On the inferior lip, the incisions are marked according to the presence of the perioral wrinkles. Small undermining is made through these incisions with tenotomy scissors to cut the orbicularis oris muscle a few millimeters above the vermilion line, taking care not to damage the superior and inferior labial arteries passing just beneath the muscle (Fig. 1). Then, an intramuscular tunnel is created using a 1.8-mm cannula, making blunt dissection across each side of the superior lip, preserving the Cupid's bow. An 18 × 1.8-mm strip of orbicularis oculi muscle is excised on each side during the superior blepharoplasty procedure. It is then pulled through the tunnel with a tendon forceps in each hemilip (Fig. 2). Finally, suture of the skin incisions at the level of the vermilion is performed with interrupted MN 6-0. Orbicularis oculi grafts used for lip augmentation produced a youthful appearance by adding natural, soft roundness and fullness to the lips (Fig. 3).

The definitive approach to lip augmentation has yet to be determined.<sup>3</sup> Many patients suitable for a lip augmentation and rejuvenation are of face-lift and blepharoplasty age and could benefit from a simultaneous lip enhancement during those procedures. Lip augmentation with superficial musculoaponeurotic system grafts and palmaris longus tendon has been described.<sup>4,5</sup> The perioral orbicularis oris my-



**Fig. 3.** Preoperative (*left*) and postoperative (*right*) views of lip rejuvenation using perioral myotomies and orbicularis oculi muscle strips.

otomies treat the perioral rhytides without the need for repeated injections and skin resurfacing procedures that in the long run are expensive. Although there is an ever-expanding list of products for lip augmentation, the artificial appearance and feel of synthetic material injected in the lips remains a problem.<sup>4</sup> The length of the strip of orbicularis oculi muscle corresponds to the length of a superior hemilip, which makes any tailoring of the graft unnecessary. No postoperative complications were noted apart from swelling, which lasts 5 to 7 days. This combination of perioral myotomies and orbicularis oculi muscle strip has not been described previously and provides another option that can be used for lip rejuvenation. Further cases need to be performed to better define long-term results.

DOI: 10.1097/PRS.0b013e3181b1bcf55e

**Enzo Rivera Citarella, M.D.**

**Aris Sterodimas, M.D., M.Sc.**

**Alexandra Condé-Green, M.D.**

Department of Plastic Surgery  
Pontifical Catholic University of Rio de Janeiro and the  
Carlos Chagas Post-Graduate Medical Institute  
Rio de Janeiro, Brazil

Correspondence to Dr. Sterodimas  
Department of Plastic Surgery  
Pontifical Catholic University of Rio de Janeiro and the  
Carlos Chagas Post-Graduate Medical Institute  
Av. Beira Mar 406  
Rio de Janeiro, Brazil

## REFERENCES

1. Guerrissi JO. Surgical treatment of the senile upper lip. *Plast Reconstr Surg.* 2000;106:938–940.
2. Clymer MA. Evolution in techniques: Lip augmentation. *Facial Plast Surg.* 2007;23:21–26.
3. Rohrich RJ, Reagan BJ, Adams WP Jr, Kenkel JM, Beran SJ. Early results of vermilion lip augmentation using acellular allogeneic dermis: An adjunct in facial rejuvenation. *Plast Reconstr Surg.* 2000;105:409–416; discussion 417–418.
4. Leaf N, Firouz JS. Lip augmentation with superficial musculoaponeurotic system grafts: Report of 103 cases. *Plast Reconstr Surg.* 2002;109:319–326; discussion 327–328.
5. Trussler AP, Kawamoto HK, Wasson KL, et al. Upper lip augmentation: Palmaris longus tendon as an autologous filler. *Plast Reconstr Surg.* 2008;121:1024–1032.

## Life after Intentional Corrosive Ingestion: Combining Esophageal Reconstruction with Aesthetic Procedures

**Sir:**

In Asian countries, a variety of corrosive substances are routinely used to soften rice before cooking and are therefore found in many kitchens.<sup>1</sup> Suicide attempts involving the ingestion of these agents are undertaken because of psychological crises. In addition to the necessary esophageal reconstruction, intensive psychological treatment immediately following the injury is of utmost importance and must be

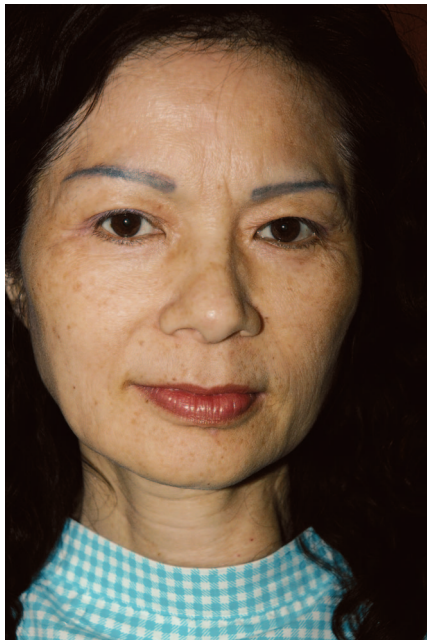carried through to the point where the patients are well equilibrated back into their environment. After accomplishing the reconstruction with techniques reported previously,<sup>2–4</sup> these patients have body image issues that are more severe than they were before the attempted suicide.

We have offered aesthetic procedures in an effort to improve their quality of life for a select group of patients who have recovered from such episodes. Between December of 2005 and May of 2006, three esophageal reconstruction patients underwent aesthetic procedures in an effort to improve their quality of life. Within 12 months after reconstruction, a combination of revision of facial and abdominal scars, bilateral upper blepharoplasty with creation of supratarsal folds, and a rhytidectomy was performed on all patients. The face lift involved elevation of skin flaps in the face through preauricular and postauricular incisions and a 4-cm submental incision. Dissection of the skin flaps in the neck is performed with caution to avoid injuring the bowel graft that is placed in the standard fashion for diversion loop procedures. A nasogastric tube was placed in all patients and used for feeding the patients for 5 days. Because of the concern for injury to the neoesophagus, the patients were given nothing by mouth for the first 5 days after surgery and then underwent esophagography to detect minor leaks that could have occurred during dissection of the neck skin. The cost of the blepharoplasties and face lifts was covered by a grant from the institution that provided funding for this study. Scar revisions were covered by the patients' health insurance.

An appearance-related quality-of-life questionnaire (Derriford Appearance Scale-24) was administered preoperatively and postoperatively to quantify patients' disfigurement caused by corrosive injury and subsequent esophageal reconstruction, and to assess improvements following aesthetic procedures. There were no complications related to the aesthetic procedures. One patient required rerevision of a scar in the neck because of recurrent scar contracture. All patients were satisfied with the surgical outcomes and felt that these procedures provided some enhancement to the quality of their lives (Figs. 1 and 2). All patients also demonstrated an improvement in their Derriford Appearance Scale-24 score postoperatively.

In conclusion, esophageal reconstruction following corrosive injury has a tremendous impact on the patient's quality of life. The addition of aesthetic procedures in a select group of patients enhances the patient's body self-confidence. The patients must be selected carefully and approached only if they ask for improvement in aesthetic outcomes (scars or issues), which should be discussed only after several months of getting to know the patient, and with adequate psychological counseling and completion of a successful esophageal reconstruction.

DOI: 10.1097/PRS.0b013e3181b1bcf267



**Fig. 1.** This 58-year-old woman underwent esophageal reconstruction with a pedicled colon and ended up with a significant amount of scarring around the neck. This photograph demonstrating the neck scar was obtained 1 year after esophageal reconstruction and before the patient underwent aesthetic procedures.



**Fig. 2.** The patient is seen at 1-year follow-up following bilateral upper eyelid blepharoplasties, a face lift, and scar revisions.

**Hung-Chi Chen, M.D.**

**Stefano Spanio di Spilimbergo, M.D.**

Department of Plastic Surgery  
E-Da Hospital/I-Shou University  
Yan-Chau Shiang, Kaohsiung County  
Taiwan, Republic of China

**Christopher John Salgado, M.D.**

Department of Plastic Surgery  
University Hospitals Cleveland  
Case Western Reserve University  
Cleveland, Ohio

**Samir Mardini, M.D.**

Division of Plastic Surgery  
Mayo Clinic  
Rochester, Minn.

**Bahar Bassiri Gharb, M.D.**

Department of Plastic Surgery  
E-Da Hospital/I-Shou University  
Yan-Chau Shiang, Kaohsiung County  
Taiwan, Republic of China

Correspondence to Dr. Chen  
E-Da Hospital/I-Shou University  
1, E-Da Road  
Jiau-shu Tsuen, Yan-Chau Shiang  
Kaohsiung County, Taiwan 824, Republic of China  
ed100002@edah.org.tw

#### **DISCLOSURE**

*None of the authors has any commercial associations that might pose or create a conflict of interest with the information presented in this article.*

#### **REFERENCES**

1. Lai KH, Huang BS, Huang MH, et al. Emergency surgical intervention for severe corrosive injuries of the upper digestive tract. *Zhonghua Yi Xue Za Zhi (Taipei)* 1995;56:40–46.
2. Chen HC, Tang YB, Noordhoff MS. Reconstruction of the entire esophagus with “chain flaps” in a case of complicated corrosive injury. *Plast Reconstr Surg.* 1989;84:980–984.
3. Chen HC, Chana JS, Chang CH, et al. A new method of subcutaneous placement of free jejunal flaps to reconstruct a diversionary conduit for swallowing in complicated pharyngoesophageal injury. *Plast Reconstr Surg.* 2003;112:1528–1533.
4. Chen HC, Tang YB. Microsurgical reconstruction of the esophagus. *Semin Surg Oncol.* 2000;19:235–245.

### **How to Repair and Cover a Ruptured Axillary Artery**

**Sir:**

**R**upture of the axillary artery is a rare entity and is usually related to either shoulder dislocation or proximal fracture of the humerus. This is the first documented case in the English language literature of an axillary artery rupture caused by a chronic radiation wound that was treated successfully with a stent graft. A pectoralis major myocutaneous flap was used to provide



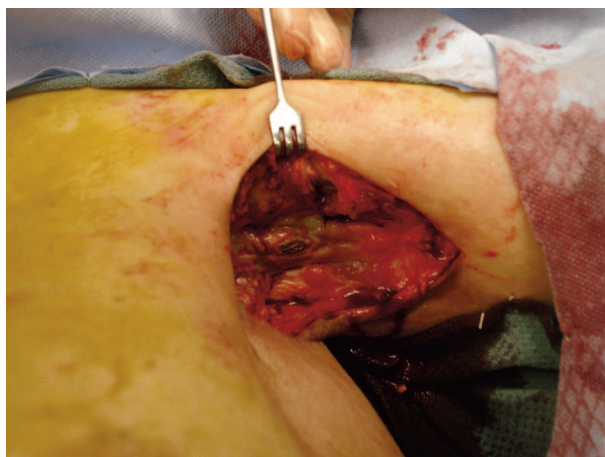a vascularized pedicle of soft tissue and skin coverage to a large axillary defect.

A 76-year-old man presented with a chronic axillary wound. Twenty-five years previously, he had undergone wide local excision of a melanoma of the left forearm and radiation therapy to the axilla. The wound measured approximately 6 × 4 cm and was 3 cm deep. The wound was very fibrotic but did not appear to be infected. His initial treatment encompassed moist local wound care, and a more aggressive approach was postponed because of a recent massive myocardial infarction.

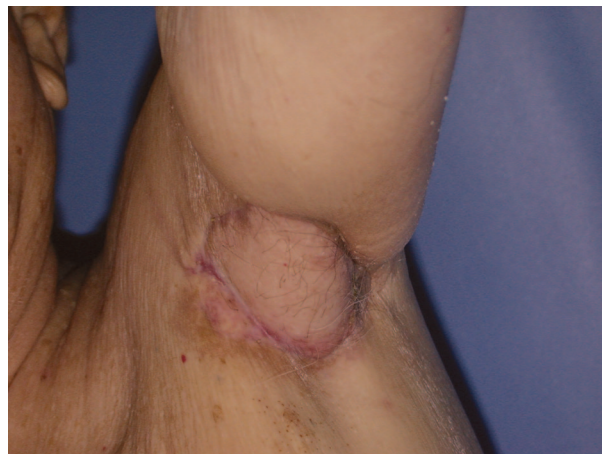However, he experienced severe hemorrhage from the left axillary artery. Primary repair of the axillary artery was unsuccessful despite attempts at débridement to “healthy” appearing arterial wall. An endovascular repair by means of the brachial artery, in the antecubital space, was performed with a covered 8-mm × 4-cm stent (Fluency; Bard, Inc., Tempe, Ariz.). Inspection of the wound identified the axillary artery with a portion of the stent exposed (Fig. 1). A layer of rehydrated acellular dermal allograft (AlloDerm; LifeCell Corp., Branchburg, N.J.) was placed at the base of the wound to prevent desiccation, and a continuous irrigation system to the axilla was started with a normal saline antibiotic solution.

The patient was returned to the operating room for a left pectoralis major myocutaneous flap with a small distal skin paddle to fit the axillary defect. The pectoralis major myocutaneous flap was raised on the thoracoacromial vascular pedicle and tunneled subcutaneously into the left axilla. The muscle was used to provide complete vascularized coverage of the axillary artery, and the skin paddle was inset into the surrounding débrided wound edges. The latissimus dorsi muscle was not used because of a severely diseased thoracodorsal artery evident on computed tomographic angiography. At his last follow-up visit 6 months postoperatively, the axilla was well healed and without signs of infection (Fig. 2).

Myocutaneous flaps provide an excellent vascularized pedicle of soft tissue with skin coverage. The



**Fig. 1.** Left axillary artery with a portion of the stent exposed.



**Fig. 2.** At follow-up visit 6 months postoperatively, the patient demonstrated a healing pectoralis major myocutaneous flap.

pectoralis major myocutaneous flap was first described in 1968 by Hueston and McConchie for the repair of an anterior chest wall defect.<sup>1</sup> The flap was popularized by Ariyan for reconstruction of the head and neck.<sup>2</sup> More recently, the pectoralis major myocutaneous flap was used to reconstruct the axilla of four patients who had melanoma recurrence after axillary dissection.<sup>3</sup>

We used the pectoralis major myocutaneous flap to cover an exposed axillary artery stent graft. This flap provided excellent bulk and protection from desiccation and further trauma to the axillary vessels. The pectoralis major myocutaneous flap is a mainstay in head and neck reconstruction because it provides an excellent vascularized pedicle of soft tissue with skin coverage. One must include the pectoralis major myocutaneous flap in one's repertoire and consider its value in reconstructing the axilla.

DOI: 10.1097/PRS.0b013e3181bcf54a

**Adam T. Silverman, M.D., M.S.**

**John M. Taylor, M.D.**

**Alfonso C. Ciervo, M.D.**

Departments of Plastic and Reconstructive Surgery and  
Vascular Surgery  
Monmouth Medical Center  
Long Branch, N.J.

Correspondence to Dr. Taylor  
Monmouth Medical Center  
300 Second Avenue  
Long Branch, N.J. 07740

## REFERENCES

1. Hueston JT, McConchie IH. A compound pectoral flap. *Aust N Z J Surg.* 1968;38:61–63.
2. Ariyan S. The pectoralis major myocutaneous flap: A versatile flap for reconstruction in the head and neck. *Plast Reconstr Surg.* 1979;63:73–81.

3. Kim JY, Ross MI, Butler CE. Reconstruction following radical resection of recurrent metastatic axillary melanoma. *Plast Reconstr Surg.* 2006;117:1576–1583.

### Dorsal Dislocation of the Lunate with Distal Radius Fracture

Sir:

**D**orsal dislocations of the lunate are exceptionally rare injuries.<sup>1</sup> A 51-year-old, right-hand-dominant man was involved in a high-speed rollover truck collision as an unrestrained passenger. He presented with a solitary complaint of severe pain of his right wrist.

His medical history included hypertension and bilateral hip replacements. He described previously untreated chronic wrist pain.

On examination, his right hand and wrist were swollen and tender, with no neurovascular injury. Radiographs demonstrated an intraarticular fracture at the base of the proximal phalanx of the fifth finger, a comminuted intraarticular fracture of the radial styloid, and a dorsal dislocation of the lunate with coexistent arthritis in the carpometacarpal and scaphotrapezotrapezoid joints (Fig. 1).

On open reduction, the lunate was found below the skin, outside the extensor retinaculum, and attached to a piece of capsule, devoid of vascular attachments. The extensor tendons were intact. There was a complete tear of the scapholunate and lunotriquetral ligaments. Almost half of the radial articular surface was comminuted.

After reduction and fixation, an attempt was made to reconstruct the dorsal capsule and dorsal and volar radiocarpal ligaments. The wrist was immobilized for 8 weeks. Radiographs at 6 weeks demonstrated reason-

able carpal alignment; the lunate appeared sclerotic and avascular (Fig. 2).

The patient returned to his previous occupation as a truck driver. One-year review revealed no functional deficit and mild wrist pain similar to his pre-injury pain.

Examination found the following: 62 percent of the uninjured flexion/extension arc (39/45 and 74/61 degrees), ulnar deviation of 20 degrees/26 degrees on the injured side, and radial deviation of 10 degrees/15 degrees. Grip strength was 68 percent (53/78 lb), tripod pinch was 60 percent (9.7/16.3 lb), and lateral pinch was 110 percent (16.6/15.6 lb) that of the uninjured side. Radiographs demonstrated arthritis and generalized osteoporosis but no evidence of avascular necrosis of the lunate. Magnetic resonance imaging was suggestive of partial lunate avascular necrosis.

Lunate dislocation is considered the final stage of a perilunate dislocation.<sup>2</sup> Typically, it dislocates volarly into the carpal tunnel. Mayfield surmised that wrist injuries are influenced by the direction and magnitude of the load and force together with properties of the involved bones and ligaments.<sup>3</sup> We think this lunate dislocated dorsally because of the force characteristics (volar to dorsal) and because of the preexisting arthritis of the scaphotrapezotrapezoid and radiocarpal joints. Because the areas of least resistance were the attenuated scapholunate ligament and space of Poirier with a relatively stable scaphoid, the lunate was dislocated. Attenuation of the perilunate ligaments limited the force required for dislocation.

An acute proximal row carpectomy would have addressed the patient's preexisting instability and arthritis. Van Kooten et al. mention an intact ra-

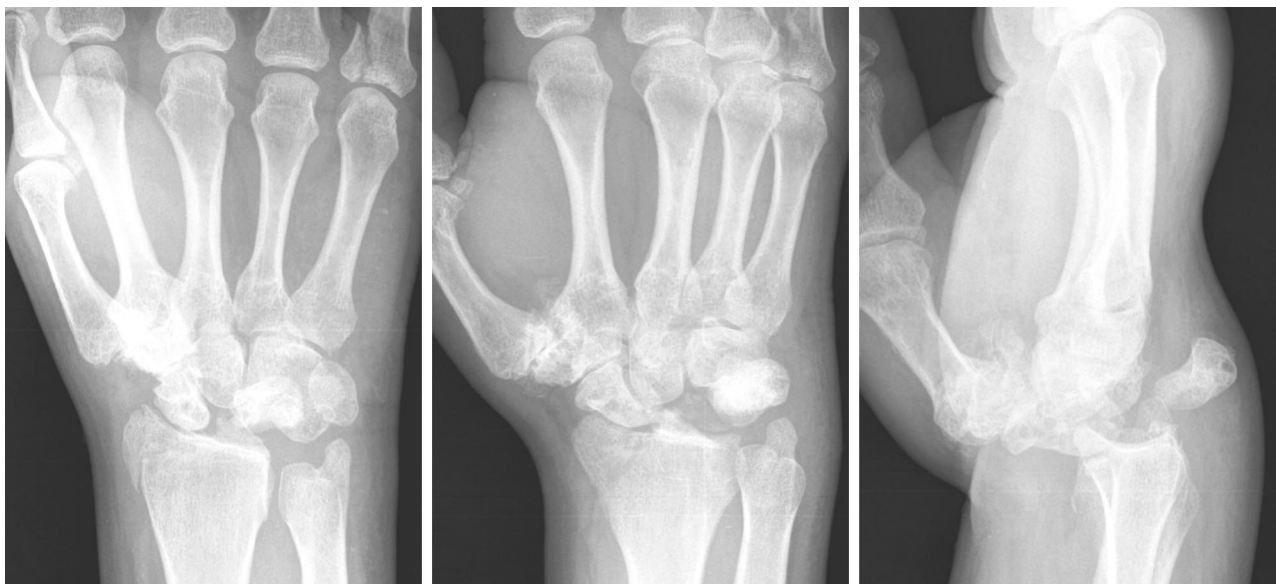
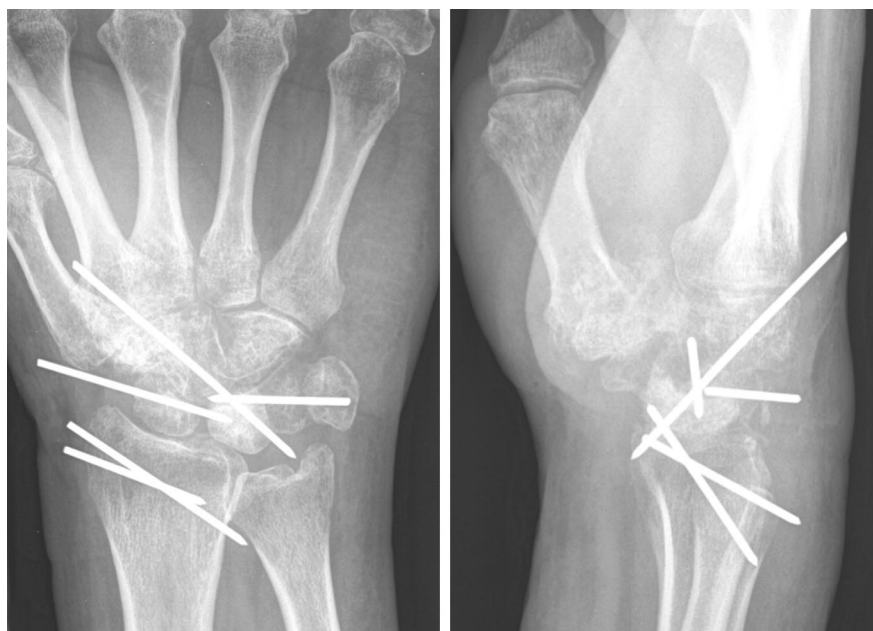


Fig. 1. Posteroanterior, oblique, and lateral views of the wrist showing dorsal lunate dislocation.



**Fig. 2.** Radiographs obtained following reduction and pinning. The lunate is sclerotic.

dioscapitocapitate ligament as a prerequisite for successful acute proximal row carpectomy, which may not have existed.<sup>4</sup>

Transient findings of increased density of the lunate or signs of avascular necrosis in the lunate following perilunate dislocation have been described.<sup>5</sup> In this case, the completely avascular lunate may have recovered partial vascularity. This, together with the good clinical result, may support attempting reduction in the acute setting over primary proximal row carpectomy.

DOI: 10.1097/PRS.0b013e3181bcf591

**Timothy Neavin, M.D.**

**W. P. Andrew Lee, M.D.**

**Ronit Wollstein, M.D.**

Department of Surgery  
Division of Plastic and Reconstructive Surgery  
University of Pittsburgh Medical Center  
Pittsburgh, Pa.

Correspondence to Dr. Wollstein  
3550 Terrace Street  
Pittsburgh, Pa. 15261  
wollsteinr@upmc.edu

## REFERENCES

1. Bilos ZJ, Hui PW. Dorsal dislocation of the lunate with carpal collapse: Report of two cases. *J Bone Joint Surg (Am.)* 1981;63:1484–1486.
2. Mayfield JK, Johnson RP, Kilcoyne RK. Carpal dislocations: Pathomechanics and progressive perilunar instability. *J Hand Surg (Am.)* 1980;5:226–241.
3. Mayfield JK. Mechanism of carpal injuries. *Clin Orthop Relat Res.* 1980;149:45–54.
4. van Kooten EO, Coster E, Segers MJ, Ritt MJ. Early proximal row carpectomy after severe carpal trauma. *Injury* 2005;36:1226–1232.

5. White RE Jr, Omer GE Jr. Transient vascular compromise of the lunate after fracture-dislocation or dislocation of the carpus. *J Hand Surg (Am.)* 1984;9:181–184.

## Bottoming Out: A Simple Technique for Correcting Breast Implant Displacement

**Sir:**

**B**ottoming out is a complication of breast implant surgery that consists of the descent of the inframammary fold with inferior displacement of the implant, causing breast asymmetry. Release of the lower pole for adjustment of the inframammary fold<sup>1</sup> can result in insufficient capsular support, and the downward pectoral muscle action can contribute to push and keep the implant in a lower position.

There are different surgical techniques with which to correct bottoming out, such as single or multilayer capsulorrhaphy with or without mirror-image selective capsulotomy, capsular flaps, polypropylene mesh, cadaveric dermis, AlloDerm (LifeCell Corp., Branchburg, N.J.), and intracapsular allogenic dermal grafts.<sup>1–5</sup> A new simple technique is presented for correcting the implant displacement recreating a new inframammary fold with an external approach.

The desired new inframammary crease is marked preoperatively in the standing position. The closed capsulorrhaphy is performed under local anesthesia. The implant must be protected, and displaced cranially with one hand to prevent accidental perforations. A 3-mm incision made with a no. 11 blade is performed at the level of the inframammary fold. A custom-made aspiration scrape cannula (2 mm in diameter) is introduced through this incision. The lower pole of the capsule is scraped with the cannula with the aim of



provoking a fibrotic process and scarring adhesions. After this, a suture is performed by means of three nonabsorbable polypropylene external stitches deep to the periosteum of the sixth and seventh ribs, creating the new desired inframammary fold following the preoperative markings. The skin is protected from the stitches using petrolatum gauze. This retention suture collapses the redundant capsule and keeps the implant in the desired position during the healing process. Stitches are removed on the fifth postoperative day. An elastic dressing to define the new submammary fold is worn for 1 week.

With this technique, the new inframammary fold is created at the desired site by means of the stitches and the capsular adhesions caused by the cannula scrape. The removal of the stitches prevents possible implant capsular erosion from the knots. It is not indicated in cases with implant displacement combined with capsular contracture.

We report the case of a 26-year-old woman who underwent an axillary subpectoral augmentation mam-

maplasty (350-cc silicone cohesive-gel implant; Mentor Corp., Santa Barbara, Calif.). In the second postoperative month, she presented a 4-cm inferior displacement of the right implant (Fig. 1). She underwent surgical correction by means of this technique.

At 12 months after the procedure, the clinical control shows an adequate implant position, without recurrence of bottoming out (Fig. 2).

We present only a case report here, although we have a short series of six patients treated successfully with this technique. This technique is an option to keep in mind because it is a simple, rapid, and useful method with which to correct bottoming out with local anesthesia, recreating a new inframammary fold with an external approach.

DOI: 10.1097/PRS.0b013e3181bcf578

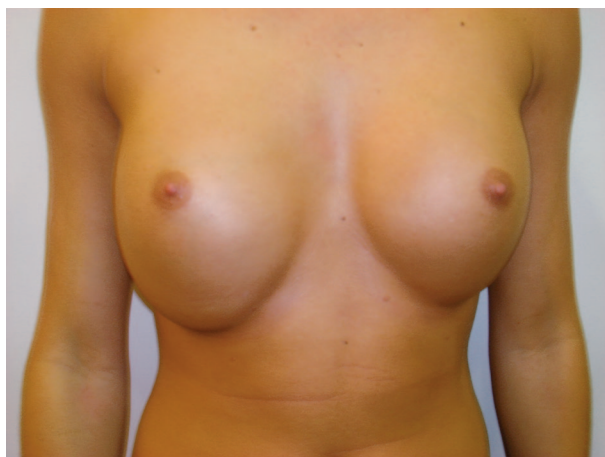Ivan Mañero, M.D.

Patricia Montull, M.D.

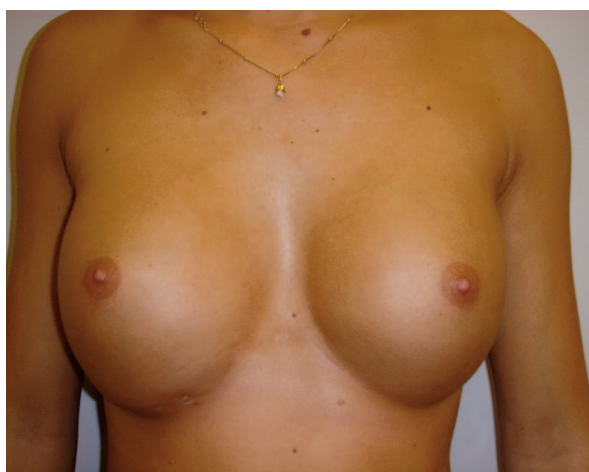Eva Guisantes, M.D.

Hospital Clínic  
Plastic and Reconstructive Surgery  
Barcelona, Spain

Correspondence to Dr. Guisantes  
Hospital Clínic  
Plastic and Reconstructive Surgery  
C/ Villarroel 170  
Barcelona 08036, Spain  
evasav@gmail.com



**Fig. 1.** Patient with bottoming out of the right breast. The right inframammary fold is 4 cm below the desired site.



**Fig. 2.** Postoperative control at 12 months.

## REFERENCES

1. Baxter R. Intracapsular allogenic dermal grafts for breast implant-related problems. *Plast Reconstr Surg.* 2003;112:1692–1696; discussion 1697–1698.
2. Chasan P. Breast capsulorrhaphy revisited: A simple technique for complex problems. *Plast Reconstr Surg.* 2005;115:296–301; discussion 302–303.
3. Spear SL. Breast capsulorrhaphy. *Plast Reconstr Surg.* 1988;81:274–279.
4. Carlsen L, Voice D. Using a capsular flap to correct breast implant malposition. *Aesthetic Surg J.* 2001;21:441–444.
5. Massiha H. Reconstruction of the submammary crease for correction of postoperative deformities in aesthetic and reconstructive breast surgery. *Ann Plast Surg.* 2001;46:275–278.

## A Modified “Fistula-VAC” Technique: Management of Multiple Enterocutaneous Fistulas in the Open Abdomen

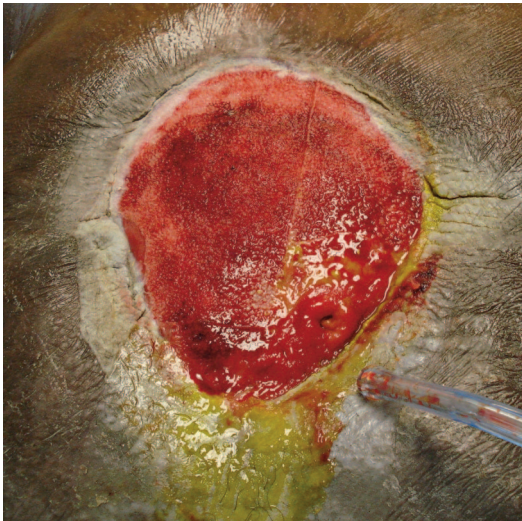
Sir:

**M**anagement of a high-output enterocutaneous fistula can be a labor-intensive and frustrating task for nursing staff, physicians, and the patient. In the presence of an open abdomen, wound management becomes extremely difficult, especially when effluent contaminates the granulating wound bed, delaying wound healing and prolonging hospital stay. The vacuum-assisted closure (V.A.C.; KCI, Inc., San Antonio, Texas) dressing has been used in patients with abdominal compartment syndrome and severe abdominal sep-

sis to aid in managing the open abdomen.<sup>1</sup> Although the “fistula-VAC” technique has been described previously for exophytic fistula, our patient’s fistulas were flush with the wound surface, making the dressing application more challenging.<sup>2</sup> We present a case of an open abdomen complicated by two juxtaposed high-output enterocutaneous fistulas at the wound edge.

The patient is an obese but otherwise previously healthy 29-year-old man that sustained multiple gunshot wounds to the abdomen. He underwent laparotomy for control of hemorrhage and contamination. His abdomen remained open secondary to abdominal compartment syndrome and severe abdominal sepsis. Subsequently, he developed two high-output (2 to 3 liters/day) enterocutaneous fistulas in the proximal jejunum that were refractory to medical therapy (Fig. 1). The fistula output required three to four vacuum-assisted closure dressing changes daily.

A multidisciplinary approach enabled the development of our modified fistula-VAC dressing technique. The wound was first cleaned with saline irrigation. Suction was used to keep the continuously draining effluent off the wound bed. DuoDerm (ConvaTec, Skillman, N.J.) was placed on the normal skin adjacent to the fistulas. The perifistula area was dried using stoma powder, and a stoma flex ring was molded to the wound/skin junction. White vacuum-assisted closure nonadherent foam was then cut to fit the wound bed, excluding the fistulas and stoma flex ring (Fig. 2), and then covered by a black vacuum-assisted closure Granu-Foam (KCI) (Fig. 3). A 2 × 2 gauze sponge was then placed over the fistulas and covered by the vacuum-assisted closure drape. The entire dressing was placed to 75 mmHg of suction. The 2 × 2 gauze pad was then cut out (Fig. 2), causing the dressing to lose suction;



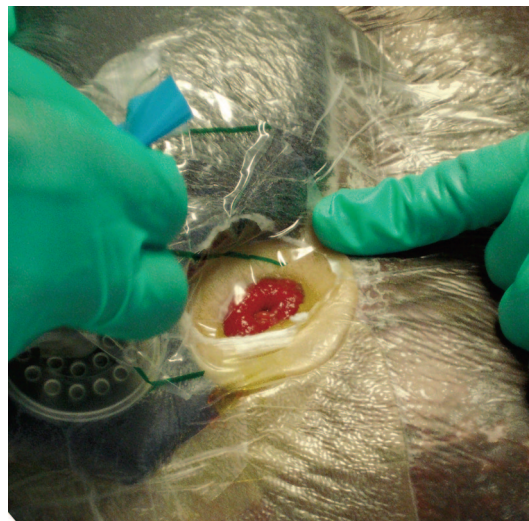**Fig. 1.** Abdominal wound with enterocutaneous fistulas.



**Fig. 3.** Placement of black vacuum-assisted closure sponge.



**Fig. 2.** Placement of white vacuum-assisted closure sponge directly on the wound bed.



**Fig. 4.** Application of additional vacuum-assisted closure drape and stoma flex ring to achieve seal.





**Fig. 5.** Application of stoma appliance to vacuum-assisted closure dressing.

however, with placement of a vacuum-assisted closure drape and an additional stoma flex ring the seal is quickly reestablished (Fig. 4). The vacuum-assisted closure device is placed to intermittent suction at 75 mmHg. Lastly, the stoma appliance and bag were placed over the fistulas and connected to a Foley bag (Fig. 5). The dressing was changed every 3 days.

Open abdominal wounds are difficult to manage, especially when complicated by an enterocutaneous fistula. We describe a modified version of the fistula-VAC for enterocutaneous fistulas that are not matured, but instead are flush with the surrounding wound bed. Overall, time to complete healing was 5 weeks from the day of initiation of the modified fistula-VAC technique. We are confident that our method can be used to control enterocutaneous fistulas when the surrounding tissues are at differing heights around the wound bed. A multidisciplinary approach created the modified fistula-VAC technique, our solution to this complex wound-healing problem.

DOI: 10.1097/PRS.0b013e3181bcf6d4

**Rocco C. Piazza, M.D.**

**Shannon D. Armstrong, M.D.**

Grand Rapids Medical Education and Research Center  
Michigan State University

**Wayne Vanderkolk, M.D.**

Department of General Surgery

**Evert A. Eriksson, M.D.**

Grand Rapids Medical Education and Research Center  
Michigan State University

**Steven L. Ringler, M.D.**

Division of Plastic and Reconstructive Surgery  
Department of General Surgery  
Grand Rapids Medical Education and Research Center  
Michigan State University  
Grand Rapids, Mich.

Correspondence to Dr. Piazza  
53 Campau Circle, NW  
Grand Rapids, Mich. 49503  
rpiazamd@gmail.com

#### ACKNOWLEDGMENTS

The authors thank Donald Scholten, M.D., professor, Grand Rapids Medical Education and Research Center, Department of General Surgery, Michigan State University; and Amanda M. McClure, B.S., Michigan State University College of Human Medicine, Grand Rapids, Michigan.

#### DISCLOSURE

The authors have no disclosures with respect to this article.

#### REFERENCES

1. Perez D, Wildi S, Demartines N, Bramkamp M, Koehler C, Clavien PA. Prospective evaluation of vacuum assisted closure in abdominal compartment syndrome and severe abdominal sepsis. *J Am Coll Surg*. 2007;205:586–592.
2. Goverman J, Yelon JA, Platz JJ, Singson RC, Turcinovic M. The “Fistula VAC,” a technique for management of enterocutaneous fistulae arising within the open abdomen: Report of 5 cases. *J Trauma* 2006;60:428–431; discussion 431.

#### Botox Treatment for Vaginismus

**Sir:**

Vaginismus is the recurrent or persistent involuntary contraction of the perineal muscles surrounding the vagina when penile, finger, tampon, or speculum penetration is attempted. In primary vaginismus, intercourse is impossible, although some of these patients are able to insert thin tampons with difficulty. Speculum examination usually causes a great deal of pain, burning, and fear. In secondary vaginismus, patients have had successful coitus and also may have given birth. There appears to be a continuum ranging from dyspareunia to mild vaginismus to severe vaginismus.

As a result of painful penetration of the vagina, patients develop an intense fear syndrome of anything that might penetrate the vagina. This often results in sweating, nausea, and vomiting.

Conservative therapy may be helpful in milder cases, consisting of Kegel exercises, psychotherapy, sex counseling, lubricants, topical anesthetics, muscle relaxants, antianxiety medications, physical therapy, and therapy with dilators. These conservative measures generally take years for the patient to accomplish the goal of being able to have intercourse. More severe cases are recalcitrant to these measures, resulting in a great deal of frustration and upheaval in relationships and marriage.

In my practice, 20 patients were treated with intravaginal Botox (botulinum toxin type A; Allergan, Inc., Irvine, Calif.) injections under sedation between 2005 and 2009. Twelve patients had primary vaginismus, five patients had secondary vaginismus, and three patients had severe dyspareunia. Twelve patients were a Lamont level 4, the most severe grade of vaginismus. Sixteen patients were able to achieve intercourse in 2 weeks to 3 months; three patients are under treatment, having advanced to the fifth or sixth of six dilators; and one



patient who was unable to advance beyond the smallest dilator is considered a failure. All patients continue to be followed, and these patients are now counseling others who have vaginismus.

Initially, lower doses of Botox were used to preserve some of the muscular activity of the vagina. With experience, higher doses (100 to 150 units of Botox) were found to be more effective in achieving complete temporary relaxation of the vagina. I currently use 2 ml of saline to dilute 100 units of Botox. This is injected in multiple areas along each lateral side of the vagina to include the bulbocavernosus, pubococcygeus, and puborectalis muscles, which are generally the areas of maximum spasm. A 1¼-inch needle and vaginal speculum are used. The procedure is performed under sedation in our surgicenter. Currently, 15 to 20 ml of 0.25% bupivacaine with 1:200,000 epinephrine is also injected into the spastic muscles and an indwelling dilator (the fifth of six dilators) coated with 2% lidocaine jelly allows the patient to wake up in recovery often experiencing pain-free penetration for the first time. This appears to speed up the time of treatment to intercourse to as early as 2 weeks. Patients usually require heavy sedation because of the amount of fear associated with any thoughts of penetration. One should be prepared and have permission to perform a hymenectomy, although this was not needed in this series of patients.

Patients are advised to use a series of graduated dilators for approximately 2 weeks before attempting intercourse. During this period, I keep in touch with my patients several times per week for support. Women find it helpful to use a dilator for approximately 30 minutes before attempting intercourse. Lubrication is essential.

Women continue to have burning and discomfort during the early attempts at intercourse, but this resolves within a few weeks. Couples are advised that during the early attempts at intercourse, the woman needs to be able to communicate her levels of comfort. Minimal penetration intercourse with minimal movement has been very helpful in allowing the woman to overcome her intense fear of pain. Sixteen of our patients (94 percent) now experience the joys of having pain-free intercourse.

In this series of women, there were no complications. There was one side effect of excessive dryness, likely caused by the action of the Botox. The parasympathetic system governs vaginal lubrication and is blocked by the action of Botox. The other patients used lubrication and did not notice any dryness. Of the successful outcomes, no patient has had a recurrence. None have had any urinary or fecal incontinence.

There is considerable psychological overlay in this population. Sexual molestation, "date rape," and strict sexual upbringing are among the factors associated with vaginismus, although often the cause is unknown. Many patients had no idea that they had a problem until their first attempted gynecologic examination or during their honeymoon. These experiences are devastating for these women.

Although 20 cases is a small series, there appear to be fewer than 60 cases reported in the English language

literature. A seminal article by Ghazizadeh and Nikzad<sup>1</sup> reported on the use of Botox in the treatment of refractory vaginismus in 24 patients. In this study, Dysport (150 to 400 mIU; Ipsen Ltd, Slough, Berkshire, United Kingdom) was used. Twenty-three patients were able to have vaginal examinations 1 week after the procedure, showing little or no vaginismus. One patient refused vaginal examination and did not attempt coitus. Of the 23 patients, 18 (78 percent) achieved satisfactory intercourse, four (17 percent) had mild pain, and one was unable to have intercourse because of her husband's impotence. A second dose of Dysport was needed for one patient. There were no recurrences during the 2- to 24-month follow-up period.

The ratio of Dysport to Botox is 2.5:1 as described by Carruthers et al.<sup>2</sup> A 1997 case report of secondary vaginismus treated first with 10 units of Botox followed by 40 units of Botox was published by Brin and Vapnek.<sup>3</sup> This patient was able to have intercourse for the first time in 8 years. The results persisted for the 24 months of follow-up.

We have received many touching emails of progress reports and thanks from our patients. Vaginismus is a very serious problem for these women. It is poorly understood, and many physicians across a number of specialties have limited experience with this entity. It is hoped that with additional awareness, physicians will have yet another modality for the treatment of vaginismus.

DOI: 10.1097/PRS.0b013e3181bf7f11

**Peter T. Pacik, M.D.**

57 Bay Street  
Manchester, N.H. 03104  
info@plasticsurgery.com

## REFERENCES

1. Ghazizadeh S, Nikzad M. Botulinum toxin in the treatment of refractory vaginismus. *Obstet Gynecol.* 2004;104:922-925.
2. Carruthers JD, Glogau RG, Blitzer A; Facial Aesthetics Consensus Group Faculty. Advances in facial rejuvenation: Botulinum toxin type A, hyaluronic acid dermal fillers, and combination therapies. Consensus recommendations. *Plast Reconstr Surg.* 2008;121(Suppl.):5S-30S.
3. Brin MF, Vapnek JM. Treatment of vaginismus with botulinum toxin injections. *Lancet* 1997;349:252-353.

## Massive Gluteal Calcinosis in a 10-Year-Old Girl with Juvenile Dermatomyositis: Successful Surgical Management

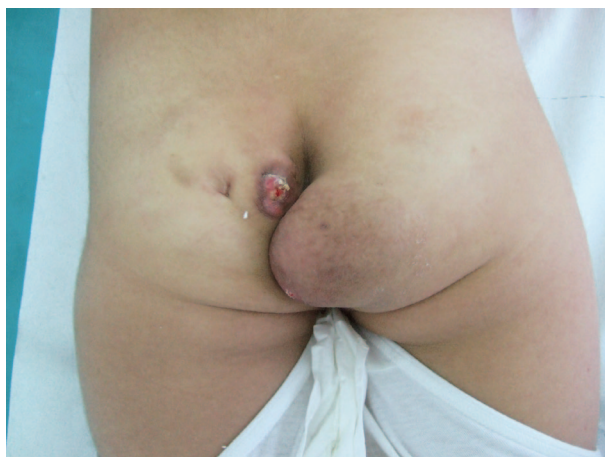**Sir:**

**C**alcinosis is a devastating complication of juvenile dermatomyositis and a challenging therapeutic problem. Juvenile dermatomyositis is a multisystemic autoimmune disease characterized by skin and muscle vasculitis. Its incidence is two to three cases per 1 million children per year.<sup>1</sup> Calcinosis in juvenile dermatomyositis is dystrophic and occurs in one-third of patients. The gluteal region is a rare and dreadful location, causing severe functional and aesthetic problems in a young girl with

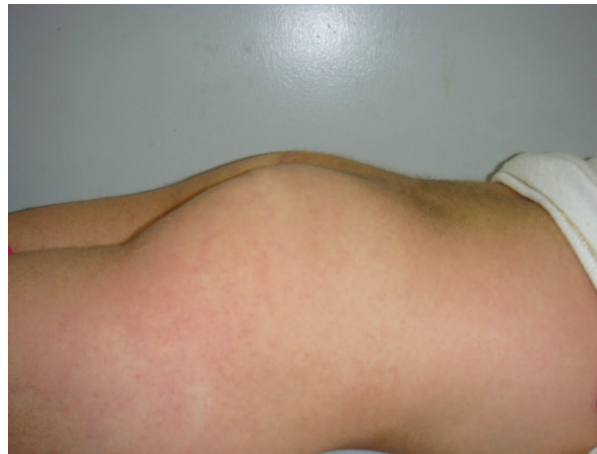juvenile dermatomyositis. Complete surgical excision was performed with a good outcome.

A 10-year-old Caucasian girl was referred to the department of pediatric rheumatology for evaluation of diffuse calcific nodules. She had been diagnosed as having juvenile dermatomyositis at the age of 7 years. Three years after diagnosis, the patient relapsed, with the appearance of multiple, firm, whitish nodules, some of which were located in both gluteal regions (Fig. 1). Routine blood tests showed normal serum calcium, inorganic phosphate, alkaline phosphatase, and parathyroid hormone. Combinations of prednisone and hydroxychloroquine were administered without improvement. The calcific painful nodules gradually increased in size and restricted her mobility. They were complicated by repeated bacterial infections resistant to medical therapy. On surgical evaluation, two subcutaneous ovular gluteal masses were detected with one fistula in the left region. The computed tomographic findings revealed no relationship with the surrounding muscles and bone. Under general anesthesia, en bloc wide excision of the masses with a functional reconstruction and gluteal remodeling was carried out. Histologic examination confirmed a dystrophic calcinosis. Antibiotic prophylaxis was administered and the patient had an uneventful postoperative evolution. Treatment with bisphosphonates and an immunosuppressant (methotrexate) was started 12 days after surgery. At 1-year-follow-up, the nodules had not recurred and the patient had not had infectious or healing complications resulting from vasculitis to which he was predisposed. An aesthetic gluteal contour was obtained (Fig. 2).

Four different patterns of dystrophic calcinosis have been described in patients with juvenile dermatomyositis: superficial plaques or nodules, deep nodular deposits that extend to the muscles, deposits along fascial planes of the muscles and tendons, and an extensive hard calcium deposit that covers the entire surface of the body. The sites frequently affected are the elbows, knees, digits, and extremities. It is believed that calcium salt deposits occur with severe juvenile dermatomyositis cases with persistent



**Fig. 1.** Preoperative appearance of the patient.



**Fig. 2.** Appearance of the patient at 1-year follow-up.

inflammation. Macrophages and proinflammatory cytokines have been observed in calcium fluids.<sup>2</sup> Treatment is based on anecdotal reports.<sup>3</sup> Bisphosphonates are a potentially promising approach through inhibition of calcium hydroxyapatite formation, macrophage function, and bone calcium resorption.<sup>4</sup> Surgical removal is indicated for patients experiencing chronic pain, loss of function, infections, or nonhealing ulcers. Potential complications of surgery include problems with wound healing and recurrence.<sup>5</sup> This tends to be uncommon with good control of the dermatomyositis before undertaking surgery; use of low doses of corticosteroids to minimize disruption to wound healing; and minimization of surgical trauma, avoiding healing by secondary intention. In conclusion, surgical resection with attention to detail with concomitant specific medical therapy is recommended for treatment of gluteal calcinosis in juvenile dermatomyositis.

DOI: 10.1097/PRS.0b013e3181bcf703

**Agata Vitale, M.D., Ph.D.**

Department of Medical and Surgical Pediatric Sciences  
Pediatric Rheumatology Unit

**Gabriele Delia, M.D., Ph.D.**

Department of Plastic and Reconstructive Surgery

**Francesco La Torre, M.D.**

**Giuseppina Calcagno**

Department of Medical and Surgical Pediatric Sciences  
Pediatric Rheumatology Unit

**Francesco Stagno d'Alcontres**

Department of Plastic and Reconstructive Surgery  
Policlinico G. Martino  
University of Messina  
Messina, Italy

Correspondence to Dr. Vitale  
Department of Paediatrics  
Rheumatology Unit  
"G. Martino" Hospital, Pad. NI  
Via Consolare Valeria  
98100 Messina, Italy  
vitale@interfree.it

**DISCLOSURE**

The authors received no support from any company or community for preparation of this article.

**REFERENCES**

1. Feldman BM, Rider LG, Reed AM, Pachman LM. Juvenile dermatomyositis and other idiopathic inflammatory myopathies of childhood. *Lancet* 2008;371:2201–2212.
2. Marhaug G, Shah V, Shroff R, et al. Age-dependent inhibition of ectopic calcification: A possible role for fetuin-A and osteopontin in patients with juvenile dermatomyositis with calcinosis. *Rheumatology (Oxford)* 2008;47:1031–1037.
3. Riley P, McCann LJ, Maillard SM, Woo P, Murray KJ, Pilkington CA. Effectiveness of infliximab in the treatment of refractory juvenile dermatomyositis with calcinosis. *Rheumatology (Oxford)* 2008;47:877–880.
4. Ambler GR, Chaitow J, Rogers M, McDonald DW, Ouvrier RA. Rapid improvement of calcinosis in juvenile dermatomyositis with alendronate therapy. *J Rheumatol.* 2005;32:1837–1839.
5. Kerstein MD. The non-healing leg ulcer: Peripheral vascular disease, chronic venous insufficiency, and ischemic vasculitis. *Ostomy Wound Manage.* 1995;42(10A Suppl):19S–35S.

### Experimental Study of the Value of Topical Irrigation in Controlling Infection of Grafted Cartilage

Sir:

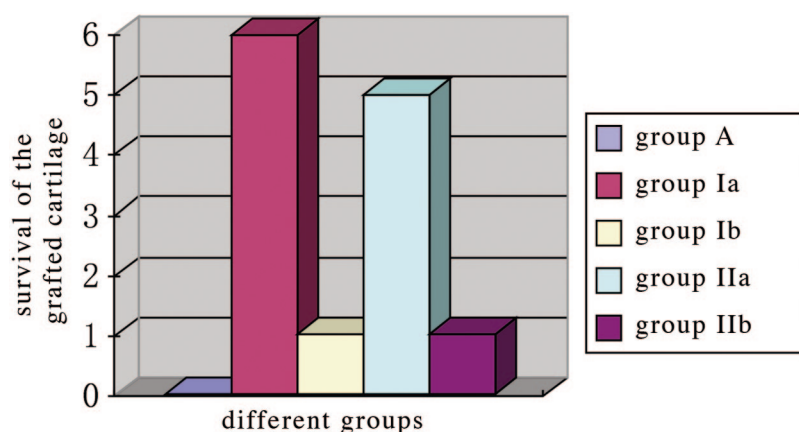
Infection of the grafted cartilage is not uncommon in plastic surgery. Generally speaking, three factors are indispensable in the process of infection. They are (1) the existence of more than a minimum amount of pathogen, (2) the conditions suitable for reproduction of the microorganism, and (3) a decrease of innate capacity of resistance to infection or the pathogenic toxicity far beyond the resistance of the host immune

ability.<sup>1,2</sup> Once the grafted cartilage is infected, in the past, surgeons had been inclined to take out the infected cartilage to control the infection. This renders the previous performance painfully invalidated.

To investigate whether topical irrigation of the infected cartilage could help to preserve the grafted cartilage and heal the wound, we planned our experiment and completed the study. To date, the rabbit has been widely and successfully used as an infective animal model.<sup>3</sup> Although the condition of the infection is different from clinical infection, we found the topical infective features to be similar to clinical changes.<sup>4</sup>

In the experiment, we established a rabbit model and carried out our research. In this process, we first established a rabbit model. The rabbit rib cartilage was extracted and implanted subcutaneously in the ventral side of the ear. We then introduced a certain amount of *Staphylococcus aureus* into the recipient site in different stages to establish an animal model with a conditioned infection. One group of six models received a conditioned infection intraoperatively. In 18 models, we successfully established the animal model through introduction of *S. aureus* into the recipient sites 1 week after survival of the grafted cartilage. After successful establishment of the animal model, we irrigated the infected cartilage with mixed antibiotic/saline solution every day. To evaluate the effectiveness of the general use of antibiotic, two groups received intramuscular administration of antibiotic, whereas the remaining two groups did not. The final outcomes were analyzed statistically.

Different results of the five infected groups existed on the basis of the conditioned infection stage and the degree of management after infection. All of the intraoperatively infected grafted cartilage unavoidably



**Fig. 1.** Different groups receiving different management had significantly different outcomes. Obviously, the topical irrigation groups (group Ia and IIa) had a higher survival rate than the nonirrigation groups (groups Ib and IIb) in salvaging the infected rib cartilages. From the experiment, we can easily draw a conclusion that early irrigation of the infected cartilage with antibiotic/saline solution could help to preserve the grafted cartilage and facilitate wound healing. This provides a guideline in clinical cartilage grafting.



necrosed. After a period of topical irrigation, the grafted cartilage survived and the infected wounds healed in all 18 rabbit models. On the contrary, the ones without topical irrigation almost necrosed whether or not they received general use of antibiotic. The results are clearly seen in Figure 1.

DOI: 10.1097/PRS.0b013e3181bf8340

**Xiaogeng Hu, M.D., Ph.D.**

**Haihuan Ma, M.D., Ph.D.**

**Peng Cui, M.D.**

**Zhiqiang Xue, M.D., Ph.D.**

**Huijie Qi, M.D.**

Plastic Surgery Department  
China Japan Friendship Hospital under Chinese Health  
Ministry  
Beijing, People's Republic of China

Correspondence to Dr. Hu  
huxiaogeng@yahoo.com.cn

### DISCLOSURE

*No economic support was derived in preparation of this article.*

### REFERENCES

1. Proctor RA, van Langevelde P, Kristjansson M, Maslow JN, Arbeit RD. Persistent and relapsing infections associated with small-colony variants of *Staphylococcus aureus*. *Clin Infect Dis*. 1995;20:95–102.
2. Van-Erp K, Dach K, Koch I, Heesemann J, Hoffmann R. Role of strain differences on host resistance and the transcriptional response of macrophages to infection with *Yersinia enterocolitica*. *Physiol Genomics* 2006;25:75–84.
3. Chambers HF. Evaluation of ceftobiprole in a rabbit model of aortic valve endocarditis due to methicillin-resistant and vancomycin-intermediate *Staphylococcus aureus*. *Antimicrob Agents Chemother*. 2005;49:884–888.
4. Moreillon P, Que YA, Bayer AS. Pathogenesis of streptococcal and staphylococcal endocarditis. *Infect Dis Clin North Am*. 2002; 16:297–318.

## One-Step Fat Harvesting Method in Lipofilling

*Sir:*

**A**utologous fat transplantation (or lipofilling) is an excellent technique that uses the patient's own body fat as a natural, living filler to achieve precise structural modifications wherever they are placed. Fat is usually harvested using a Luer-Lok syringe attached to a two-hole harvesting cannula. After refinement, the fat is transferred to a smaller syringe and then placed in the recipient site using blunt infiltration cannulas.

On several occasions in our department, we needed a huge quantity of fatty tissue to correct severe defects. An alternative means of harvesting autologous fat was found to reduce operative time and to preserve the integrity of fatty tissue parcels. We adopted a closed suction drain attached to a two-hole harvesting cannula (Fig. 1) to obtain a continuous, nonmanual, low-power negative pressure to move adipocytes, through the can-

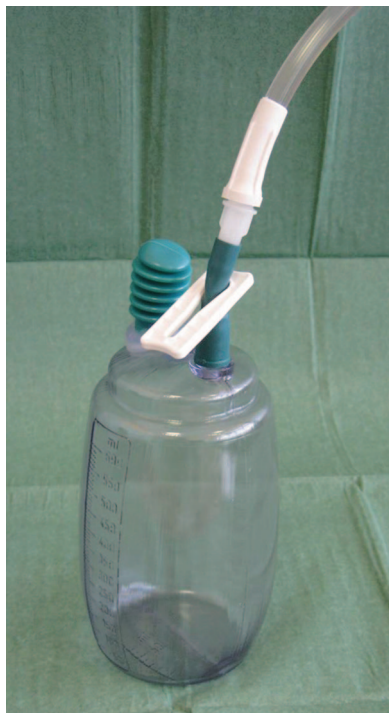nula and the tube, into the drainage bottle. Because the power suction of the drain of  $-675$  mmHg has been demonstrated experimentally to result in the breakage and vaporization of fat cells, destroying their ability to be successfully transplanted,<sup>1,2</sup> the drain is opened and a new, lesser negative pressure of  $-75$  mmHg is obtained by accelerator liposuction machine (Figs. 2 and 3). This pressure is maintained until the cannula is beneath the skin. As soon as the operator needs to change the donor region, the drain is closed at the distal end of the tube (near the drainage bottle) to preserve suction pressure and opened again once the cannula is pushed through the new harvest site to restart the suction. As the quantity of fatty tissue reached is enough, the draining bottle is cut and the fat prepared for the refinement. The procedure (refinement, transfer, and placement of fatty tissue) goes on as usual.<sup>3</sup>

This one-step harvesting modification is an extremely useful and time-saving method that can be used to ease routine technique in high-volume replacement lipofilling. Furthermore, fat harvested with an atraumatic, low-negative-pressure drain method preserves as many intact and viable lipocytes for transfer as does the manual method using a Luer-Lok syringe, and certainly more than the continuous active suction machine (liposuction). Therefore, it seems reasonable to believe that even when high quantities of fatty tissue are necessary, our method would allow successful long-term graft take anyway, providing durable and predictable cosmetic outcomes in the recipient sites.

DOI: 10.1097/PRS.0b013e3181bcf6ee



**Fig. 1.** A closed suction drain attached to the two-hole harvesting cannula represents an extremely useful method for harvesting a large quantity of fat in less time than can be accomplished manually by the syringe method.



**Fig. 2.** The drain is open and connected to the accelerator liposuction machine; the new lighter negative pressure is then obtained.



**Fig. 3.** An exact suction pressure of  $-75$  mmHg is reached into the drain. The same maneuver should be performed every time negative pressure is lost during harvesting.

**Davide Lazzeri, M.D.**

**Giordano Giannotti, M.D.**

**Livio Colizzi, M.D.**

Plastic and Reconstructive Surgery and Burn Center Unit  
Hospital of Pisa  
Pisa, Italy

Correspondence to Dr. Lazzeri  
Unità Operativa di Chirurgia Plastica e Ricostruttiva  
Ospedale di Pisa  
Via Paradisa 2  
Cisanello, 56100 Pisa, Italy  
davidelazzeri@gmail.com

#### **ACKNOWLEDGMENT**

*The authors are grateful to Gustavo Di Gaeta for help in performing this study.*

#### **DISCLOSURE**

*The authors have no financial interest in any of the products or devices mentioned in this article.*

#### **REFERENCES**

1. Witort EJ, Pattarino J, Papucci L, et al. Autologous lipofilling: Coenzyme Q10 can rescue adipocytes from stress-induced apoptotic death. *Plast Reconstr Surg.* 2007;119:1191–1199.
2. Coleman SR. Structural fat grafting: More than a permanent filler. *Plast Reconstr Surg.* 2006;118:108S–120S.
3. Kaufman MR, Bradley JP, Dickinson B, et al. Autologous fat transfer national consensus survey: Trends in techniques for harvest, preparation, and application, and perception of short- and long-term results. *Plast Reconstr Surg.* 2007;119:323–331.

### **A Simple and Reliable Technique for Harvesting Skin from a “Spare Part” by a Single Operator**

**Sir:**

**T**he harvest and application of a split-thickness skin graft is one of the most frequently performed procedures in reconstructive surgery. Regardless of the donor site, the principles for successful harvest are the same: adequate tension on the donor skin, an even donor surface, and a slippery donor surface.<sup>1</sup> When these criteria are not met, reliable harvest usually requires more than one operator.

Surgeons have described techniques for harvesting split-thickness skin grafts in situations where they are operating alone or with an inexperienced assistant. Aslam used traction sutures placed in four quadrants to stabilize and restore surface tension when taking skin grafts from elderly patients with loose, unstable thigh skin.<sup>2</sup> Zeligowski and Ziv advocated suturing tissue that had been avulsed back to its original site under adequate tension to allow standard dermatome harvest.<sup>3</sup> Goris and Nicolai used two assistants to stretch the avulsed tissue over gauze or over the patient’s uninjured thigh to restore conditions for successful harvest.<sup>4</sup>

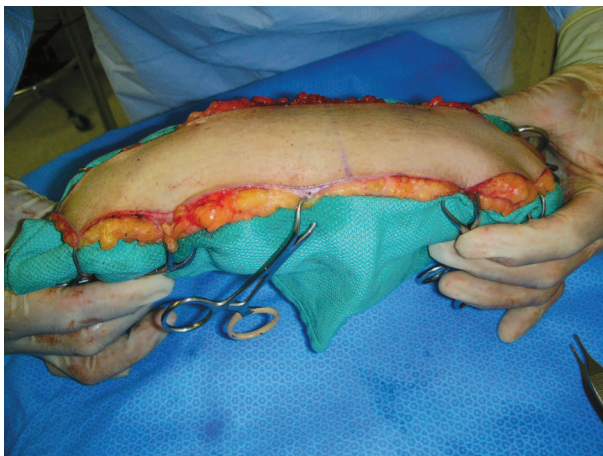

We previously described miniabdominoplasty during rectus abdominis muscle harvest for extremity reconstruction.<sup>5</sup> The dermolipectomy specimen was treated as a “spare part” for skin graft harvest. The purpose of this report is to describe our simple and reliable technique for harvesting split-thickness skin from a spare part by a single operator.

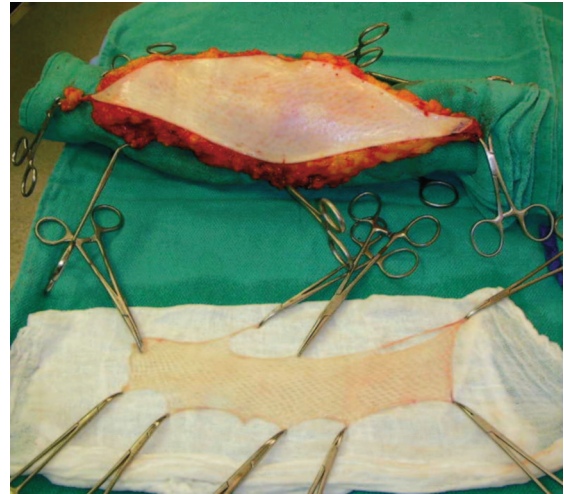
The tissue is placed over rolled operating room towels and secured with towel clamps, such that peripheral traction is applied re-establishing skin tension and a uniform surface. The clamps are placed in the dermal layer to keep their edges clear of the dermatome guide, guaranteeing unobstructed harvest (Fig. 1). After mineral oil is applied, a single operator can grasp the towel clamp at the apex of the bolstered tissue and apply stable traction against the advancing dermatome. Alternatively, a Weck blade may be used for smaller tissue harvest. Figure 2 demonstrates the harvested skin graft with the spare part.

Over a 2-year period, 25 patients underwent a combined procedure of rectus abdominis muscle harvest with a miniabdominoplasty. In these patients, the dermolipectomy tissue was used as a spare part for split-thickness skin grafting. A single operator harvested the skin graft with a Paget dermatome or Weck blade using the described technique. The average quantity of tissue harvested was 150 cm<sup>2</sup> (range, 100 to 250 cm<sup>2</sup>). Twenty-three of 25 patients (92 percent) did not require additional grafting. The remaining two patients required less than 50 cm<sup>2</sup> of additional split-thickness skin graft.

The benefits of this technique are multiple. For the surgeon, the technique is simple to perform and the result is reliable. It requires no specialized equipment other than what would be used in standard skin graft harvest. A single operator without skilled assistance can accomplish it. The patient is spared the morbidity of a skin graft donor site entirely, or benefits from a smaller donor site. A thicker, more durable skin graft may be harvested from the spare part without further conse-



**Fig. 1.** Miniabdominoplasty spare part secured with towel clamps to re-establish skin tension and a uniform surface. Clamps are placed in the dermal layer and secured to towels.



**Fig. 2.** Harvested and meshed skin graft from a spare part.

quence to the patient. In addition, the patient receives the welcome dividend of an improved abdominal contour.

DOI: 10.1097/PRS.0b013e3181bcf253

**Darrell Brooks, M.D.**

**Sendia Kim, M.D.**

**Rudolf F. Buntic, M.D.**

Buncke Clinic  
Department of Microsurgical Transplantation and  
Replantation  
Davis Campus  
California Pacific Medical Center  
San Francisco, Calif.

Correspondence to Dr. Brooks  
45 Castro Street, Suite 121  
San Francisco, Calif. 94114  
dbrooks@microsurgeon.org

## REFERENCES

1. Ablove RH, Howell RM. The physiology and technique of skin grafting. *Hand Clin.* 1997;13:163–173.
2. Aslam A. A new method to facilitate skin graft harvest with minimal assistance. *Ann Plast Surg.* 1999;43:101–102.
3. Zeligowski AA, Ziv I. How to harvest skin graft from the avulsed flap in degloving injuries. *Ann Plast Surg.* 1987;19:89–90.
4. Goris RJ, Nicolai JP. A simple method of taking skin grafts from the avulsed flap in degloving injuries. *Br J Plast Surg.* 1982;35:58–59.
5. Brooks D, Buntic RF. An aesthetic requisite of rectus muscle transplantation in extremity reconstruction. *Ann Plast Surg.* 2005;54:109–111.

## A New Approach for Humanitarian Missions

*Sir:*

**N**umerous humanitarian missions are targeted toward the correction of hare lip and cleft palate. During these missions, the main shortcoming is the difficulty of organizing patient follow-up in such a way



as to render local medical services autonomous. If we analyze the situation of the health systems in areas where these humanitarian missions are being carried out, what becomes clear is the difficulty in identifying worthy health systems that are capable of offering an adequate level of safety in both surgery and anesthesia and that meet those standards that are almost universally accepted and followed. It is this which should be the focus of future humanitarian missions, changing pure surgical operations, which are limited to working in the present day, and making true medical and surgical centers where patient follow-up is ensured over time.

It was in this frame of mind that we recently created a highly functional surgical center in Nassirya, working in collaboration with the governments of both Italy and Iraq. Thanks to the availability of a specific task force that was set up within the Italian Ministry of Foreign Affairs to help the people of Iraq, a mobile surgical center has been donated to the southern region of Iraq and has been transported overland from Virginia, through Kuwait, to the Iraqi base at Talill. The mobile surgical center (Fig. 1) is transportable thanks to an accompanying lorry, and provides adequate space for an operating theater (Fig. 2) and a postoperative recovery room.

In this context, a group of 16 staff that includes surgeons, anesthetists, and nurses has managed to carry out 66 surgical operations and 88 surgical procedures on patients aged between 5 months and 17 years, according to the protocol, for anesthesia and surgery, of the Smile Train organization.

Throughout this 11-day mission, 15 Iraqi doctors and nurses played an active role during both the surgical and the preoperative and postoperative phases. The involvement of surgeons and anesthetists was made more concrete by means of the activation of a program of telemedicine that we believe to be of such extreme importance that it should become part of the resource bank of all humanitarian missions.

The ideal scenario would certainly be that of creating such a highly specialized health model in an existing



Fig. 1. The mobile surgical unit.

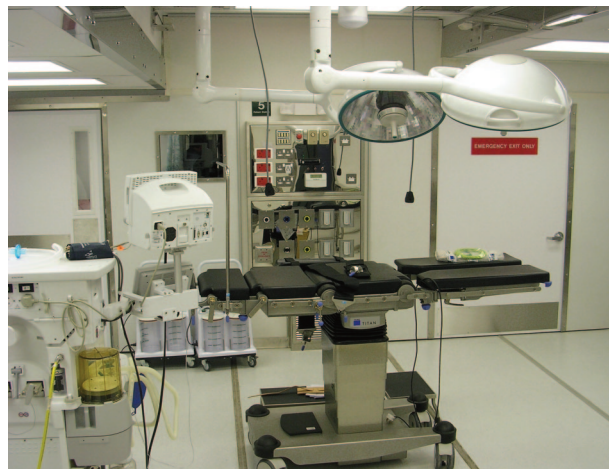

Fig. 2. The surgical room.

hospital, but this seems unrealizable in the current political climate, which does not permit humanitarian missions to work freely and with the necessary security. However, this freedom and security are available at the Iraqi base of Talill and are allowing us to make this ambitious project a reality over a 3-year time period.

We believe that the best way for humanitarian organizations to proceed is by the promotion of training and support for local medical personnel and the provision and maintenance of equipment for these centers with the overall aim of developing their autonomy. Our model, using a mobile unit, may be one that can be used in other situations of specific difficulty, such as that in Iraq, where it is dangerous to work in the field.

DOI: 10.1097/PRS.0b013e3181bcf23f

**Fabio Massimo Abenavoli, M.D.**

“San Pietro” Hospital  
Fatebenefratelli  
Smile Train Onlus Italia  
Rome, Italy

Correspondence to Dr. Abenavoli  
Via Savoia 72  
00198 Rome, Italy  
f.abenavoli@mclink.it

## The “Chain of Reliance” in Plastic Surgery

*Sir:*

**P**lastic surgeons must be able to be trusted to act in the way expected. This means that we must trust “responsible” people that act as shackles of a complicated system of control (chain of confidence) and are indispensable for suitable outcomes.

We give credit to Mauricio Parada, M.D., our mentor and professor of surgery who always gave us this information during surgery residency.<sup>1</sup>

In the “team work,” the surgeon is only one part of this chain. To trust each one of the links of the chain is a precondition for good performance of any enter-

prise. A failure of any part of the chain is recipe for disaster.

Plastic surgeons travel often, and the best example of a chain of confidence is a commercial airline flight. A disaster is always possible: a pilot under stress and possibly under the influence of drugs, flight assistants who fail to close the door of the airplane firmly, and so on. After some time working in a university hospital, we give six examples that clarify this idea in plastic surgery:

1. A bone graft was delivered from the hip for a case of nasal reconstruction. The scrub nurse received the implant and the team continued to finish the reconstruction. The surgeon asked for the bone, but the nurse answered that it was discarded as “she thought it was only traumatologic debris.”
2. An abdominoplasty case finished without incident. The patient was moved from the operating room table to her bed, but the resident had “stepped on top of the recipient of the Foley catheter”; forced traction produced extrusion of the bladder (mucosa) that needed further urologic surgery.
3. In another abdominoplasty case, during transfer of the patient from the operating room table to the bed, “the drains were left underneath the mattress” and were pulled out of the wound. The patient underwent reoperation and the drains were reinstalled with the aid of endoscopy.<sup>2</sup>
4. A liposuction case was recovering in the postanesthesia room, where the nurse confused the urine recipient with a water trap recipient used in lung surgery and connected the system to the wall suction. The patient suffered shock and intense pain that needed treatment with morphine and stabilization in the intensive care unit.
5. An upper blepharoplasty case was performed under sedation and local anesthesia and controlled by an anesthesiologist that refused to use a mask to deliver oxygen. The result: fire in the operating room.<sup>3</sup>
6. After a transverse rectus abdominis musculocutaneous flap, the patient was recovering in a sitting position. The nurse measured the debits of the drains, putting the bed in the horizontal position with the consequence of a dehiscence and bleeding of the abdominal wound.

The plastic surgery team operates with a sequence of events and multiple personnel—including the anesthesiologist, operating room assistants, recovery room nurses, and others—until the patient is back in his or her room and discharged from the hospital.

Faith and truth are synonyms of confidence when they are used in the sense of a chain of reliance that starts with the patient and his or her safety. The analogy of “perfect teamwork” is the truth and “bad teamwork” the lie; the truth is constructed as a tower of cards that will resist the

final destruction if the cards are put in the correct order; the lie is constructed with failure of a part of the chain, and the missing card determines the final collapse of the tower.

When a chain of confidence (plastic surgery team) works in both ways, the organization is internally competitive and even more competitive to the sector and subsectors. Reliance is a “top-10 concept” during the surgeon-patient communication. Allegiance of plastic surgery patients is based in sound principles, objectives, results, and expectations.

Organizations such as the International Society of Aesthetic Plastic Surgery and the American Society of Plastic Surgeons have worked in constant support on behalf of safety and play an important role as mediators between the shackles of the chain of reliances. Finally, protecting a chain of confidence will make any enterprise more competitive and recommendable.

DOI: 10.1097/PRS.0b013e3181bf7ff5

**Arturo S. Prado, M.D.**

**Francisco Parada, M.D.**

Plastic Surgery Division  
Department of Surgery  
Jose Joaquin Aguirre Clinical Hospital  
University of Chile School of Medicine  
Santiago, Chile

Correspondence to Dr. Prado

#### DISCLOSURE

*The authors have no conflicts of interest to disclose.*

#### REFERENCES

1. Parada M. Personal communication, 1999.
2. Prado A, Parada F. Accidental “pull-out” of drains after abdominoplasty: Outpatient endoscopic control of an expanding hematoma and re-installation of drains under direct vision without opening the wound. *Plast Reconstr Surg*. 2009;123:79e–120e.
3. Prado A, Andrades P, Fuentes P. Fire in the operating room after reading a CME. *Plast Reconstr Surg*. 2007;119:770–773.

#### Postablative Reconstruction Is Better Terminology than Oncoplastic Surgery

Sir:

*Art, indeed, consists in the conception of the result to be produced before its realisation in the material.*

—Aristotle in *De Partibus Animalium (On The Parts Of Animals)*, 350 BC

Ongoing innovations continue to advance effective surgical primary tumor control and are linked to improved surgical outcomes, minimized patient morbidity, and better quality of life. The term “oncoplastic” was first used in 1996.<sup>1,2</sup> It originates from the Greek words *onkos* (ογκος), meaning bulk, mass, or tumor;

and *plastikos* (πλαστικός), meaning molded or shaped. These words together mean the molding of a tumor. This term is therefore unsatisfactory when applied to the combination of oncology surgery and plastic surgery.

Surgery is the oldest modality of cancer therapy and still forms the mainstay of treatment for solid tumors. Surgery operates by zero-order kinetics, in which all excised cells are killed. Ablation derives from the Latin *ablatus*, the irregular past participle of *aufferre*, to carry away (*ab-*, away; plus *tatus*, carried); it now has a specifically surgical edge, and today it applies principally to the surgical removal of any part of the body.<sup>3</sup>

During the past two decades, major improvements in both operative technique and the use of combined-modality therapy have significantly reduced the morbidity and mortality associated with the surgical treatment of solid neoplasms. For example, breast-preserving surgery has become an alternative to mastectomy in patients with breast carcinoma, and limb salvage is often possible in patients with bone and soft-tissue sarcomas. Advances in microvascular surgery now permit the free transfer of complex autologous tissues, such as free jejunal grafts to reconstitute the upper aerodigestive system or osteomyocutaneous flaps to reconstruct extremities and other mobile body parts such as the jaw.

Intuitively, it appears logical that the term “postablative reconstruction” is an appropriate term for the specialized art of surgery devoted to the restoration of form and function after the surgical removal of solid tumors.

DOI: 10.1097/PRS.0b013e3181bf7fe3

**Sammy Al-Benna, M.R.C.S., Ph.D.**

**Lars Steinsträßer, M.D.**

Klinik für Plastische Chirurgie und Schwerbrandverletzte  
BG Kliniken Bergmannsheil  
Ruhr-Universität  
Bochum, Germany

Correspondence to Dr. Al-Benna  
Klinik für Plastische Chirurgie und Schwerbrandverletzte  
BG University Hospital Bergmannsheil  
Ruhr-Universität  
Bürkle-de-la-Camp-Platz 1  
44789 Bochum, Germany  
sammyalbenna@doctors.org.uk

## REFERENCES

- Hüter J. Tumor-adapted oncoplastic mastopexy and reduction-plasty (in German). *Zentralbl Gynakol*. 1996;118:549–552.
- Gabka CJ, Bohmert H. Future prospects for reconstructive surgery in breast cancer. *Semin Surg Oncol*. 1996;12:67–75.
- Compact Oxford English Dictionary* (Web site). Available at: [http://www.askoxford.com/concise\\_oed/ablation](http://www.askoxford.com/concise_oed/ablation). Accessed June 22, 2008.

## Composite Tissue Allografts: Should We Reconsider the Terminology?

**Sir:**

Composite tissue allotransplantation is a rapidly progressing field of reconstructive transplant surgery. This surgical specialty refers specifically to the transplantation of composite tissue allografts. The first successful transplant involving a composite tissue allograft was performed in 1957 by Dr. Peacock. This operation involved the transplantation of a human flexor tendon allograft in a 47-year-old woman suffering from tenosynovitis of her index finger.<sup>1</sup> Since then, numerous allografts have followed, which include hand, partial face, knee (vascularized joint), abdominal wall, larynx, uterus, vascularized nerve, and scalp.<sup>2</sup>

The objective of this letter is to acknowledge my personal disliking of the descriptive term, “composite tissue allograft.” As one of the editors for the textbook entitled *Transplantation of Composite Tissue Allografts*,<sup>2</sup> I feel compelled to report my dissatisfaction. Personally, the term “composite tissue allograft” is misleading, and plastic surgeons, transplantologists, physicians, immunologists, and scientists alike may need to revise this terminology.

For example, the word “graft” is used to describe “tissue that has been removed from the body, is completely devascularized, and is relocated to another location dependent on recipient neo-vascular ingrowth for survival.”<sup>3</sup> As for the definition of an allograft, it is defined as “tissue transplanted between unrelated individuals of the same species.”<sup>4</sup> Furthermore, “a group of two or more tissues containing more than one germinal layer” is known as a “composite graft.”<sup>5</sup>

Therefore, in summary, a composite tissue allograft, by the strictest sense of the aforementioned definitions, would accurately describe “devascularized tissue(s) transplanted from a donor to an unrelated recipient, and whose survival/function is solely dependent upon recipient neo-angiogenesis.” This definition does not, and should not, allude to transplanted tissue(s) possessing inherent vessels and/or nerves requiring microsurgical anastomoses, such as in the case of many composite tissue allografts.

Hand transplantation, for instance, is often described as being a “composite tissue allograft.”<sup>5</sup> Obviously, the hand allograft is *not* dependent on the recipient for establishing neurovascularity and that, in fact, it is accomplished by its own nerves (i.e., median, ulnar, and radial) and vessels (i.e., radial/ulnar arteries, cephalic/basilic veins) requiring microanastomoses. Therefore, I propose that we use a more accurate term such as “composite tissue allotransplant,” or for more detail, refer to this particular composite tissue allotransplantation subtype as a “composite tissue limb allotransplant.”

Another great example is the partial face allograft, which has been performed recently in both France and China.<sup>2</sup> These successful “allografts” contain skin, subcutaneous tissue, muscle, and of course, their own inherent nervous tissue (i.e., facial nerve) and blood supply (i.e., external carotid artery, external jugular/facial veins), and



again require microsurgical anastomoses during transplantation, unlike a typical graft. Perhaps, instead of using the term “facial composite tissue allograft” to describe this type of reconstructive surgery, we should be using a term more analogous, such as “facial composite tissue alloflap” or “free composite allotissue transfer” instead.

In conclusion, no matter which terminology is chosen, composite tissue allotransplantation is a uniquely fascinating subspecialty, and I look forward to witnessing many unprecedented clinical achievements in the near future.

DOI: 10.1097/PRS.0b013e3181bf7fd1

**Chad R. Gordon, D.O.**

Department of Plastic Surgery  
The Cleveland Clinic  
9500 Euclid Avenue, Desk A-60  
Cleveland, Ohio 44195  
drchadrgordon@hotmail.com

**REFERENCES**

1. Peacock EE Jr, Madden JW. Human composite flexor tendon allografts. *Ann Surg.* 1967;166:624–629.
2. Gordon CR, Serletti JM, Black KS, Hewitt CW. The evolution and current status of composite tissue allotransplantation: The twentieth century realization of “Cosmas and Damian.” In: Hewitt CW, Lee WPA, Gordon CR, eds. *Transplantation of Composite Tissue Allografts.* New York: Springer; 2008:13–25.
3. Thorne CH. Techniques and principles in plastic surgery. In: Aston SJ, Beasley RW, Thorne CHM, eds. *Grabb and Smith's Plastic Surgery.* 6th ed. Philadelphia: Lippincott-Raven; 2007:8.
4. Lee WPA, Feili-Hariri M, Butler PEM. Transplant biology and applications to plastic surgery. In: Aston SJ, Beasley RW, Thorne CHM, eds. *Grabb and Smith's Plastic Surgery.* 6th ed. Philadelphia: Lippincott-Raven; 2007:53.
5. Baker DC. Composite grafts. In: Georgiade GS, Riefkohl R, Levin LS, eds. *Georgiade Plastic, Maxillofacial and Reconstructive Surgery.* 3rd ed. Baltimore: Williams & Wilkins; 1997:34.