

# Open Abdomen With Concomitant Enteroatmospheric Fistula: Validation, Refinements, and Adjuncts to a Novel Approach

Salomone Di Saverio, MD, Silvia Villani, MD, Andrea Biscardi, MD, Eleonora Giorgini, MD,  
and Gregorio Tugnoli, MD

**Key Words:** Acute care surgery, Open abdomen, Frozen abdomen, Intestinal fistula, Controlled fistula drainage, Vacuum dressing therapy, Abdominal sepsis.

(*J Trauma*. 2011;71: 760–762)

In our Trauma and Acute Care unit we have adopted and been using VAC therapy (KCI) for open abdomen management for a while, having had experience in 24 cases. In their experience, Layton et al.<sup>1</sup> describe their simplistic but brilliant in design technique for managing the challenging coexistence of open abdomen and intestinal fistula in a trauma patient setting.

The aim of diverting the fistula output away and separately from managing with vacuum aspiration the frozen abdomen is clever and effective at the same time. The attempt of formation of a “controlled” fistula while promoting clean granulation over the bowel and diverting contamination might be an acceptable strategy in severely ill patients and in challenging “surgical nightmare” frozen abdomen with intestinal fistula.

In October 2010, we have been facing a similar situation, when a 46-year-old man was admitted for complete adhesive small bowel obstruction and suspicion of strangulation of a parastomal hernia. He underwent an abdominoperineal Miles’ resection for rectal cancer when he was only 24 years old. In October 2010, after admission, laparotomy and an extensive adhesiolysis were performed, and direct repair of parastomal hernia was performed. The bowel was strangulated but not yet ischemic.

On postoperative day 7, the patient became hypoxic and agitated. The abdomen was grossly distended, tender at palpation with guarding. White blood cells were 30,000/cm<sup>3</sup>.

Submitted for publication January 8, 2011.

Accepted for publication February 15, 2011.

Copyright © 2011 by Lippincott Williams & Wilkins

From the Emergency Surgery and Trauma Surgery Unit, Trauma Center, Department of Emergency, Department of Surgery, Maggiore Hospital, Bologna, Italy.

Supplemental digital content is available for this article. Direct URL citations appear in the printed text, and links to the digital files are provided in the HTML text of this article on the journal’s Web site ([www.jtrauma.com](http://www.jtrauma.com)).

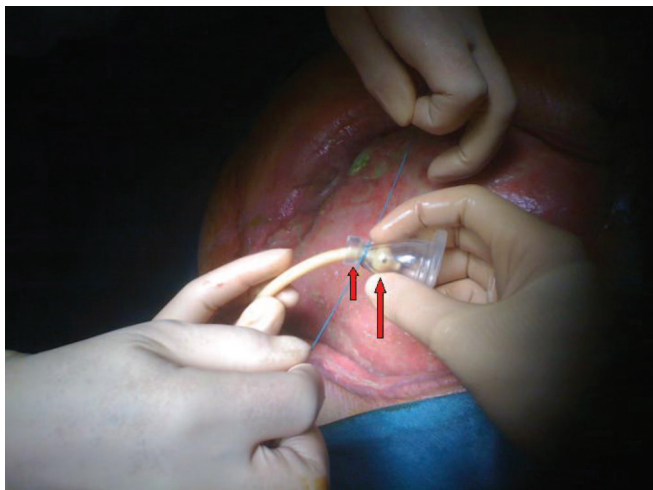
Address for reprints: Salomone Di Saverio, MD, Attending Surgeon. L.G.O. Nigrisoli 2, 40100, Bologna, Italy; email: [salo75@inwind.it](mailto:salo75@inwind.it).

DOI: 10.1097/TA.0b013e318216e340

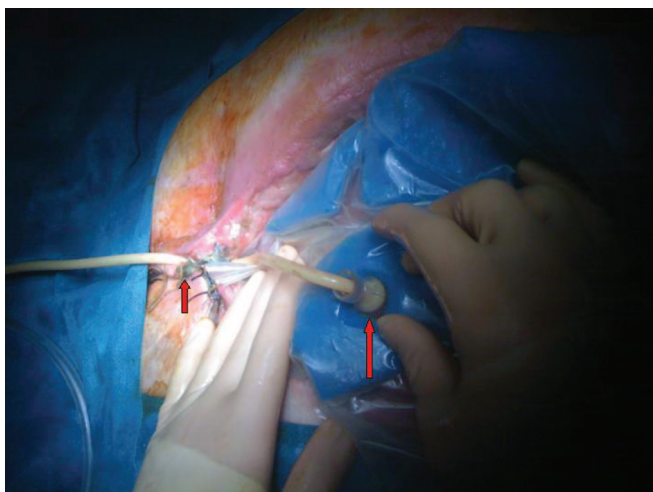
Urgent computed tomography scan showed a considerable amount of abdominal-free fluid with distended ileal loops, in the absence of free air.

At relaparotomy, two ileal perforations were found with diffuse enteric peritonitis, within an extensive and dense adhesive small bowel condition. The decision at this stage was to perform a simple repair of the perforations with fibrin glue adjunct. Open abdomen with Bogota Bag (VAC dressing without vacuum) was then decided. After 2 days, the second look showed good seal of the ileal perforations. VAC therapy with proper vacuum aspiration (125 mm Hg) was initiated. After three cycles of VAC therapy changes and 6 days of treatment, the intraoperative finding of a fistula leak from one of the previous repair dramatically changed the perspectives. At this point, a new attempt of repair was done with Vicryl stitches and fibrin glue,<sup>2</sup> which revealed to be unsuccessful in few hours, developing a high-output leaking fistula.

Keeping in mind the experience from Layton et al., Dr. Di Saverio, Attending Surgeon of the Emergency and Trauma Surgery Unit, has therefore decided to adopt this novel approach, which is recently described. As advised, after proper irrigation for reducing contamination, a baby bottle nipple of soft silicone was used and placed over the fistula, located in the lower hypogastrium, just under the closed lower edges of the midline incision. The tip of the baby nipple was cut, and a small size Petzer tube, “ad hoc” shaped, was pulled through the hole (Fig. 1; see supplement digital content Video 1, <http://links.lww.com/TA/A52>). The Petzer tube was secured and sealed to the tip of the nipple by a tied nonabsorbable stitch (Fig. 1; SDC Video 1, <http://links.lww.com/TA/A52>). The complex nipple-tube was passed through an “ad hoc” shaped hole in the VAC dressing (Fig. 2; SDC Videos 2 and 3, <http://links.lww.com/TA/A53> and <http://links.lww.com/TA/A54>). The baby nipple was held in place by the hands of the assistant while the operator was properly positioning the VAC dressing (Fig. 2). The tube was finally passed between the skin stitches of the lower midline incision, with intent of holding the nipple in place and sealed to the bowel surface (Fig. 2). The VAC dressing was finally positioned, and the plastic was placed to cover the sponges and shaped around the Petzer tube draining the fistula coming out from the wound, to achieve a complete seal and allow an effective vacuum suction (Fig. 3; SDC Video 4, <http://links.lww.com/TA/A55>). VAC was started at 100 mm Hg (Fig. 3; SDC Video 4, <http://links.lww.com/TA/A55>). The method was effective for the first 24 hours; however, thereafter a leak from the nipple

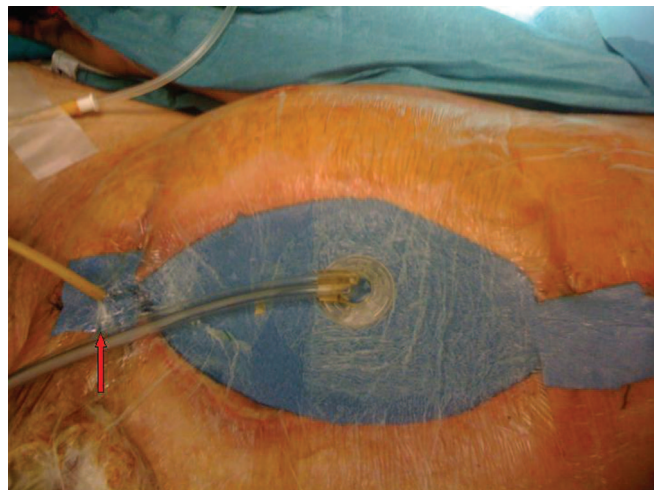


**Figure 1.** First step of the technique initially described by Layton et al. and preparation of a baby bottle nipple of soft silicone and a small size Petzer tube. The small size Petzer tube been pulled through the hole made in the tip of the baby nipple and secured and sealed with a tied nonabsorbable stitch. *Long red arrow:* small size Petzer tube pulled through the baby bottle nipple after cutting its tip (*short red arrow*).

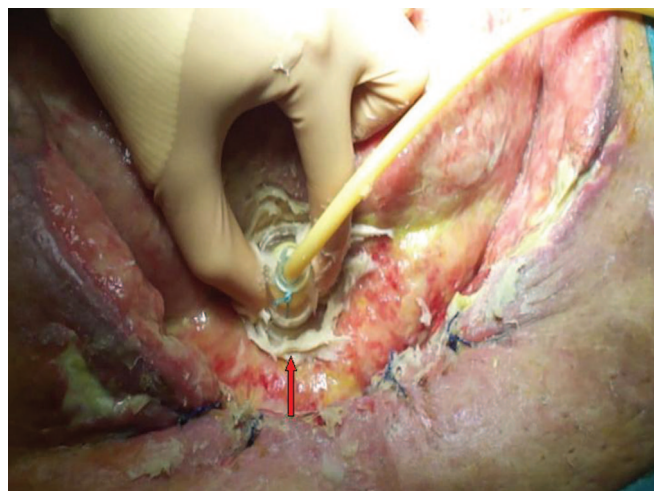

**Figure 2.** The complex nipple-tube passed through an "ad hoc" shaped hole (*long red arrow*) in the VAC dressing and covers the fistula hole; the tube was passed between the skin stitches of the lower midline incision (*short red arrow*), with intent of holding the nipple in place.

developed, probably because of a displacement during nursing maneuvers and enteric fluid evacuation from the VAC suction. During the redo of the VAC dressing, we have attempted to fix and improve the potential mistakes and limitations of this technique. First, we tried to expose as much as possible the fistula (Fig. 5) and, by opening the lower part of the wound, to better exteriorize the fistula hole toward outside and therefore minimize intraperitoneal leaks (SDC Video 5, <http://links.lww.com/TA/A56>). Second, a better seal



**Figure 3.** VAC dressing positioned and the plastic covering the sponges and shaped around the Petzer tube draining the fistula and coming out from the wound, to achieve a complete seal and allow an effective vacuum suction. The VAC drapes and sponges remodeled to allow the tube passage through them and help holding the tube (*red arrow*). Wrapping of a transparent waterproof adhesive film dressing (Tegaderm) around the tube. Overview of the system after vacuum aspiration started. A better sealing and proper positioning of the nipple and good "atmospheric" exposure of the fistula area may allow a better control and exclusion of the fistula output and a more effective VAC suctioning for a faster granulation.



**Figure 4.** Ensuring an effective barrier to leakage from the baby nipple using colostomy paste between the bowel and the nipple is essential. Colostomy paste is placed on the edges of the nipple (*red arrow*) and a paste layer filled the surrounding cavity, excluding the area of the fistula, to avoid strain of bowel content. Pressure to achieve a proper seal of the nipple complex over the bowel.

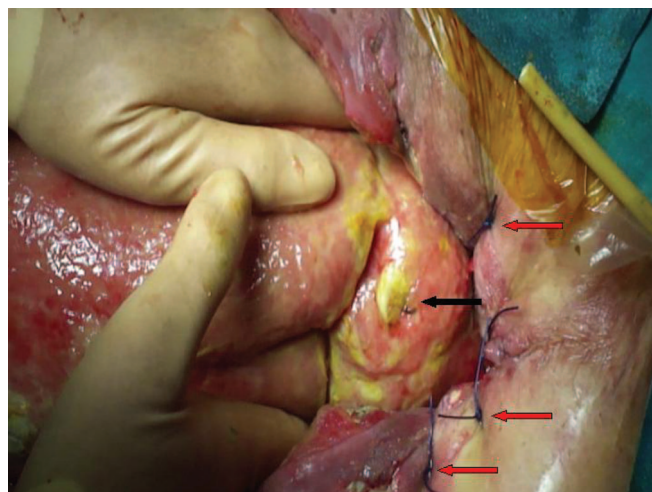
was achieved by placing the nipple over an underlying layer of colostomy paste (as advised by Layton et al.) and a jelly gauze around the nipple, covering the bowel and excluding the area

of fistula (Fig. 4; SDC Video 6, <http://links.lww.com/TA/A57>). The VAC drapes and sponges were remodeled accordingly to allow the tube passage through them and help holding the tube in place. A better sealing and proper positioning of the nipple and good “atmospheric” exposure of the fistula area allowed a better control and exclusion of the fistula output and a more effective VAC suctioning for a faster granulation (Fig. 3).

However, in the subsequent VAC changes, leaks have often occurred from the nipple-tube complex. In an attempt to further optimize both the sealing of the fistula and avoiding or at least limiting the displacement of the nipple, we developed and applied an adjunct to the technique of Layton et al. by inserting a small size (10 Fr) Foley catheter into the fistula hole, slightly inflating the balloon with 2 cm<sup>3</sup> to 3 cm<sup>3</sup> of water. The Foley catheter tube was then passed through and secured to the silicone nipple neck for optimal drainage and seal of the fistula site, positioning the nipple as described above.

In conclusion, in case of a challenging frozen abdomen, either in posttraumatic or in acute care surgery setting, the management of a concomitant fistula may be a nightmare. This is a clever and easy technique for managing open abdomen with concomitant intestinal fistula. Attention should be paid when fistula is located deeply and internally and does not have a sufficient and a plane horizontal exposure on the external surface of the frozen bowel. In these cases, keeping the nipple appropriately oriented over and perpendicular to the fistula opening maybe hardly achievable.

An additional trick should be trying to exteriorize as much as possible the fistula outside the abdominal cavity (by opening or enlarging the wound incision and/or stitching and approximating the edges of the skin on the remnant of the sheet; Fig. 5; SDC Video 5, <http://links.lww.com/TA/A56>), especially when the fistula opening is not already well exposed, as in our case. Ensuring an effective barrier to leakage from the baby nipple using colostomy paste between the bowel and the nipple is essential. A proper seal of the VAC dressing around the exteriorization of the complex nipple-Petzer tube can be obtained by wrapping a transparent waterproof adhesive film dressing (Tegaderm) around the tube (SDC Video 7, <http://links.lww.com/TA/A58>). Attention should also be paid in mobilizing the patient during nursing because the complex nipple-tube can be easily dislodged and the system may leak. Appropriate exposure of the fistula,



**Figure 5.** Appropriate exposure of the fistula outside the abdominal cavity (by opening or enlarging the wound incision and/or stitching and approximating the edges of the skin on the remnant sheet). *Black arrow:* enteroatmospheric fistula hole within the frozen abdomen; *red arrows:* stitches approximating the edges of the skin on the remnant of the sheet for a better exposure and isolation of the fistula.

proper seal of the nipple with colostomy paste, and effective dressing wrapping are useful tricks to keep in mind for avoiding dislodgement of the system. Finally, the adjunct of inserting a Foley catheter into the fistula hole, coming out through the nipple, with the double rationale to effectively drain the bowel and seal the possible leaks from the fistula as well as to prevent or at least minimize the displacement of the baby nipple-tube complex, may improve the efficacy of this technique. This adjunct may be useful in selected cases when is needed to reliably anchor the baby nipple over the fistula and control the fistula output.

The technique first described by Layton et al. is useful, low in cost, and easily reproducible.

## REFERENCES

1. Layton B, DuBose J, Nichols S, Connaughton J, Jones T, Pratt J. Pacifying the open abdomen with concomitant intestinal fistula: a novel approach. *Am J Surg.* 2010;199:e48–e50.
2. Girard S, Sideman M, Spain DA. A novel approach to the problem of intestinal fistulization arising in patients managed with open peritoneal cavities. *Am J Surg.* 2002;184:166–167.