

# Use of the Rectus Abdominis Muscle Flap for Repair of Enterocutaneous Fistulae: A Case Series

*Christopher Schneider, MD, James Wallace, MD, James Fowler, MD, Richard Roettger, MD, and Benjamin Manning, MD*

A fistula is considered complex when abdominal connective tissue and fascia are lost due to infection or debridement, exposure to caustic substances or retraction, as seen in the prolonged open abdomen. These fistulae are essentially enteroatmospheric, because they have no corresponding abdominal wall fat or fascia between the bowel lumen and the outside world. They often occur after bowel is exposed for a prolonged period of time and can exist as either small or large intestinal fistulae. In the literature, the mortality of these patients is noted to be as high as 80% with a nearly universal morbidity.<sup>1</sup> Early control and characterization of the fistulae are imperative as these patients can easily become malnourished and septic. Because the spontaneous closure rate of these fistulae is exceedingly low (<30% in some series), creative management and assistance in closure are often necessary.<sup>1,2</sup> Although the recommended surgical management technique is resection of the involved fistulous bowel with reapproximation of the patient's fascia, the complex fistula does not permit this occasionally.<sup>3,4</sup> These are the cases that are more demanding in terms of both surgical and medical management.

Complex wound care arrangements, skin grafting, and various devices and techniques have been identified to help gain control and assist in closure of the enterocutaneous fistula.<sup>5</sup> When those techniques fail or the patient is deemed unable to undergo further extensive wound care and multiple attempts at closure, one option to provide a vascularized pedicle of tissue for closure of the fistula is the rectus abdominis muscle flap. The purpose of this discussion is to describe in detail the technique itself, explain its rationale for use, and present our first six consecutive cases along with their outcomes using this technique.

## PATIENTS AND METHODS

### Patient Selection

Patients were selected after discussion of all treatment options at open conference on an individual case-by-case

basis to receive a rectus muscle flap for treatment of their fistula. Patients were selected due to medical management issues or fistula management concerns. In those who were due to medical management, the primary issue was fluid and electrolyte loss, leading to dehydration and severe electrolyte depletion. In those who were due to surgical issues, four patients had undergone multiple attempts at control of their fistula effluent that included, but were not limited to, skin grafting, negative pressure wound dressings, nonadherent wound dressings, large caliber drains, and fistula tubes. The remaining two patients had multiple reoperations and a "frozen abdomen" excluding reexploration and resection of the fistulous bowel. All patients failed individual management techniques over time at which point their fistula was deemed terminal. Six patients were selected to receive this treatment modality between the years 2005 and 2010. All are included in our series.

### Technique

Initial patient management includes characterization and control of the fistula. Computed tomography assured the absence of abscess or distal obstruction and contrasted fistula studies were added to characterize the location of the fistula when the location of origin was uncertain. Sepsis, if present, was managed with antibiotics, drainage, and resuscitation. Parenteral nutrition was used when necessary (5 of the 6 patients total), and once the fistula effluent was controlled, attempts at closure were made with a variety of accepted techniques.

Those patients who required operation were taken to the operating room. The fistula was identified, and necrotic skin and soft tissue were debrided until healthy tissue was identified. The rectus sheath was then identified. In one patient, the ipsilateral rectus fascia and muscle had been destroyed by necrotizing infection and therefore only one rectus muscle remained. The rectus sheath was then exposed and opened, revealing the rectus abdominis muscle. The muscle was harvested by using the dual blood supply based on the inferior or superior epigastric artery (Fig. 1). Blood supply selection was based on the best way to achieve a tension-free rotation and inset for the muscle flap. The dual blood supply of the rectus muscle allows for full mobilization and coverage of the entire anterior abdominal wall (Fig. 1).

The fistula is then closed with absorbable suture in a single layer. The rectus muscle flap is then rotated, again based on the superior or inferior epigastric artery, to cover the

Submitted for publication April 22, 2010.

Accepted for publication January 5, 2011.

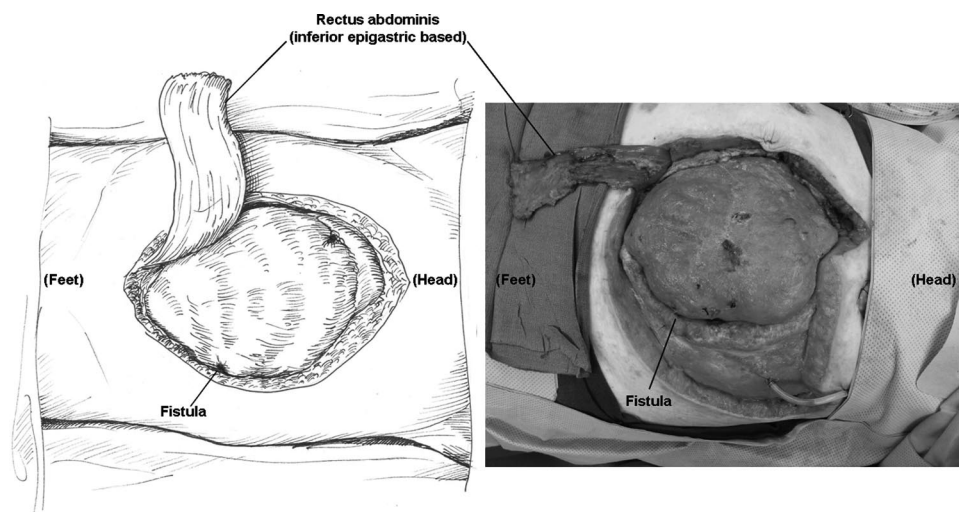
Copyright © 2011 by Lippincott Williams & Wilkins

From the Department of Surgery, Greenville Hospital System University Medical Center, Greenville, South Carolina.

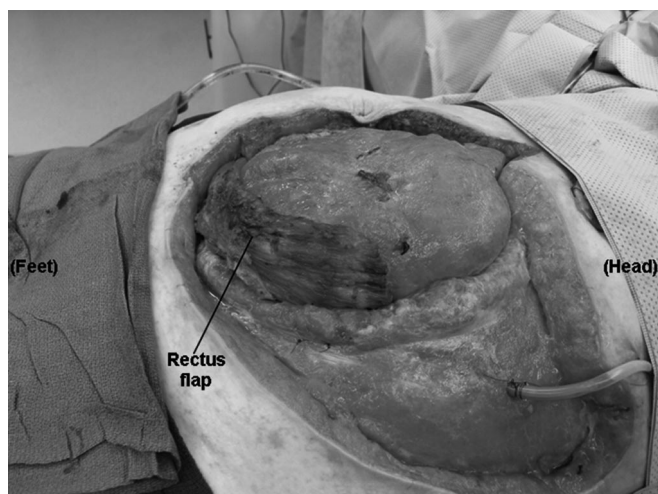
Presented at the 40th Annual Meeting of the Western Trauma Association, February 28–March 6, 2010, Telluride, Colorado.

Address for reprints: Christopher Schneider, MD, 108 Crown Empire Ct, Simpsonville, SC 29681; email: cschneider@ghs.org.

DOI: 10.1097/TA.0b013e31820ea1c5



**Figure 1.** Artistic rendering of a rectus abdominis muscle flap based on the inferior epigastric artery along with the procedure performed on a patient with a complex fistula after necrotizing fasciitis infection.



**Figure 2.** The mobilized, inferior epigastric-based, rectus flap. This muscle has been rotated to cover the fistula in the right lower quadrant (Fig. 1).

fistula (Fig. 2). The flap is secured to any available fascia. If no fascia is available, the flap is merely rotated to the position covering the fistula and subsequently held in place with the negative pressure dressing. The wound is first dressed by using a nonadherent dressing (Petrolatum) and then a negative pressure dressing (vacuum) is placed. This is then set to  $-75$  mm Hg continuous suction and left for 4 days to 5 days.

On postoperative day 5, the dressing is taken down and replaced if necessary. This wound treatment is continued until the wound bed is deemed acceptable for skin grafting by the treating physician.

## RESULTS

This technique has been used in the six patients during a 5-year period. All patients had high-output, small bowel complex fistulae (enteroatmospheric) and previous open ab-

dominal wounds. Time to cessation of fistula output after flap coverage ranged from 3 days to 5 days. All patients had an initial drainage of what seemed to be small bowel contents (succus) at 2 days to 3 days, but all had ceased and fistula closed at the time of initial dressing change. This was thought to be related to the suture used to “close” the fistula, a step that may not be necessary. Skin grafting was performed at 1 week to 6 weeks after the initial placement of the rectus flap. Skin graft timing was dependent on subjective granulating wound appearance and patient stability. All patients had  $>80\%$  of initial skin graft taken and none required regrafting for coverage. All patients were discharged home at the time of preparation of this article. Long-term follow-up has been maintained for five of the six patients with the remaining patient  $<1$  month out from fistula repair. Currently, there have been no flap or patient failures in our series. Table 1 depicts in detail the characteristics of patient and fistula.

## DISCUSSION

Enterocutaneous fistulae most often develop as a complication after bowel surgery, but they are also frequent in cases of the open abdomen, trauma, radiation, and occasionally occur spontaneously.<sup>6</sup> A majority of these fistulae occur in the postoperative setting and are more common after emergency surgery, as in the acute care or trauma disaster, or in the debilitated or malnourished patient.<sup>6</sup> High-output, small bowel fistulae are the most common presentation of the disease process and when the patient has lost the abdominal wall fat, fascia, or muscle, management becomes increasingly difficult. The large bowel fistula and the low-output fistula can persist and present difficulty in closure despite all the appropriate steps being taken as well. These patients may also require a more complex closure using the rectus flap when all other management attempts have proven unsuccessful.

The mainstays of patient management include fistula effluent diversion and output volume assessment.<sup>5</sup> Patient resuscitation and electrolyte repletion can be difficult but are

**TABLE 1.** Patient Cases Along With Contributing Factors and Attempted Management Before Rectus Flap, of Note There Are No Recorded Recurrences With Reasonable Follow-Up

	Patient 1	Patient 2	Patient 3	Patient 4	Patient 5	Patient 6
Initial cause	Diverticulitis	Diverticulitis	Ovarian cancer	Necrotizing fasciitis	Blunt trauma	Hernia repair
Contributing factors	Anastomosis leak	Anastomosis leak	Abdominal irradiation	Open abdomen	Open abdomen	Bowel injury
Fistula location	Small bowel	Small bowel, colon	Small bowel	Small bowel	Small bowel	Small bowel
Previous management	Resection/repair	Complex wound care*	Abdominal drains, complex wound care*	Skin graft	None	Complex wound care*
Reason for failure	Frozen abdomen <sup>†</sup>	Malnutrition	Lack of vascularized tissue, irradiation	Electrolyte management	Electrolyte management	Frozen abdomen <sup>†</sup>
Nutrition status (albumin/protein)	2.5/7.3	1.3/4.9	2.5/6.1	2.1/6.2	2.2/4.8	2.3/5.0
Fistula duration (wk) <sup>‡</sup>	1	19	2	20	1	13
Time to closure (d)	3	5	5	3	4	8
Time to skin graft (wk)	3	8	5	7	3	2
Recurrence	No	No	No	No	No	No

\* Complex wound care includes the use of any technique outside of simple wet to dry dressing changes or skin grafting.

<sup>†</sup> Frozen abdomen refers to multiple previous operations precluding successful resection and reanastomosis of the fistula.

<sup>‡</sup> "Fistula duration" describes the length of time from fistula identification to rectus abdominis flap placement.

essential to allow for long-term survival.<sup>5</sup> In addition, before any surgical intervention, evaluation for distal obstruction and abscess presence must be performed. In the malnourished patient, or the high-output fistula, initiation of total parenteral nutrition should be considered early in the disease course.<sup>7</sup> In addition, the wound should be meticulously monitored and cared for to prevent further tissue loss or fistula formation.

Despite even ideal management, spontaneous closure of the complex fistula can be expected in <30% of cases.<sup>1,2</sup> If possible, the surgical management of choice in these patients is to resect fistulous bowel with primary reanastomosis along with abdominal fascial closure. If this is unable to be accomplished in the acute setting, a staged operation including fascial release may be required. In severe cases, the fistula recurs or persists despite optimal management. Initial attempts should be made to control the fistula and skin grafts, negative pressure dressings, fistula tubes, may be necessary to accomplish this result. In the most severe cases, where other interventions have failed or medical management is impossible, creative surgical management may be necessary.

Patients who received a muscle flap in this series were thought to have minimal chance of fistula closure, and their concomitant medical comorbidities and instability led to this treatment option. Patients with a short (or nonexistent) fistulous track, a history of radiation to the abdomen or abdominal wall, or those who have a scarred in abdomen have an altered anatomy making it difficult to find a vascularized pedicle of tissue with which to cover their fistula and thus provide the necessary blood and nutrient supply to encourage healing.<sup>8</sup> These patients require internalization, omental, or intestinal bolstering of their anastomosis or fistula, or some other means to encourage healing without further fistula formation.<sup>9</sup> These specific situations are the ones thought to benefit most from using the muscle flap. In these situations, it allows coverage of the wound, nutrient supply to a nutrient-poor

setting, and a suitable site for future skin grafting and wound closure. In addition, as we progressed in our use of the technique, we were far more aggressive in the use of the flap as we thought that early repair stood a better overall chance of closure than if we allowed the fistula to "mature."

Mobilization and manipulation of the rectus sheath and the internal and external rectus fascia have consequences. The maneuver itself will limit future attempts at abdominal wall reconstruction and makes fascial components separation exceedingly difficult if not impossible. This predicament should be considered before surgical intervention and should not be taken lightly as potential loss of abdominal domain and other hernia issues may be a cause of long-term morbidity.

Individual case reports were identified in the literature describing the use of this technique in a patient with a duodenal fistula after a gunshot wound and in a patient who underwent postoperative radiation treatment for gastric cancer. Both described the technique similar to the one described. Both healed to skin grafting and presumed long-term survival.<sup>8,10</sup> This is the first case series depicting the technique and its success.

The weakness of this series lies in the infrequent use of the procedure for the reasons outlined above. The small numbers have not allowed sufficient raw patient data for statistical analysis and deeper understanding of the factors that may influence success or failure in these settings. These could include, but are not limited to, factors that we did not measure, such as burden of infection or injury, pre-morbid condition, or nutritional status. Because of the retrospective nature of this case series, we were only able to report static nutritional status as indicated by albumin and protein levels. Other variables were not measured and therefore were unable to be reported. Therefore, additional patients and reports from multiple institutions are necessary to pool results and outcomes in the future.

Although the ideal treatment for the enterocutaneous fistula still remains resection of the fistulous bowel and reapproximation of the abdominal fascia, there are patients who are unable to undergo such a procedure.<sup>4,5</sup> When medical or surgical complications result in persistent, high-output fistulae, the rectus abdominis muscle flap should be considered to assist in healing and intestinal closure in these patients.

### REFERENCES

1. Schien M, Decker GAG. Gastrointestinal fistulas associated with large abdominal wall defects: experience with 43 patients. *Br J Surg*. 1990;77:97–100.
2. Soeters PB, Ebeid AM, Fischer JE. Review of 404 patients with gastrointestinal fistulas. *Ann Surg*. 1979;190:189–202.
3. Marinis A, Gkiokas G, Anastasopoulos G, et al. Surgical techniques for the management of enteroatmospheric fistulae. *Surg Infect (Larchmt)*. 2009;10:47–52.
4. Sriussadaporn S, Sriussadaporn S, Kritakayakirana K, Pak-art R. Operative management of small bowel fistulae associated with open abdomen. *Asian J Surg*. 2006;29:1–7.
5. Campbell A, Chang M, Fabian T, Franz M, et al. Management of the open abdomen: from initial operation to definitive closure. *Am Surg*. 2009;75(11 Suppl):S1–S22.
6. Berry SM, Fischer JE. Classification and pathophysiology of enterocutaneous fistulas. *Surg Clin North Am*. 1996;76:1009–1017.
7. McFayden BV, Dudrick SJ, Rudberg RL. Management of gastrointestinal fistulas with parenteral hyperalimentation. *Surgery*. 1973;74:100–105.
8. Chang P, Chun JT, Bell JL. Complex enterocutaneous fistula: closure with the rectus abdominis muscle flap. *South Med J*. 2000;93:599–602.
9. Lui RC, Friedman R, Fleischner A. Management of postirradiation recurrent enterocutaneous fistula by muscle flaps. *Am Surg*. 1989;55:403–407.
10. Mauldin JM, Ciraulo DL, Guest DP, Smith PW, Lett DE, Barker DE. Contralateral rectus abdominis myofascial transposition flap closure of an anterior abdominal wall lateral duodenal cutaneous fistula after shotgun injury to the abdomen. *J Trauma*. 2006;60:1353–1357.